

**ezine**  
**ifssh**  
CONNECTING OUR GLOBAL HAND SURGERY FAMILY

IFSSH EDUCATIONAL  
SPONSORSHIPS

HAND THERAPY  
EXERCISE PRESCRIPTION APP

# Constriction Ring Syndrome



"HAND SURGERY RESOURCE"  
MERGES WITH IFSSH

IFSHT EVELYN MACKIN  
CONGRESS GRANT



## *To new adventures and old friendships*

The International Federation of Societies for Surgery of the Hand (IFSSH) looks forward to the year ahead when we will reconnect with many old friends and welcome a new generation of hand surgeons to the IFSSH family - starting with the first ever IFSSH Mid-Term Course in January, hosted by the Ecuadorian Society.

We wish hand surgeons throughout the world all the very best for 2024.

Daniel Nagle, President  
 S. Raja Sabapathy, President Elect  
 Marc Garcia-Elias, Immediate Past President  
 David Warwick, Secretary-General  
 Jin Bo Tang, Communications Director  
 Gregory Bain, Member-at-Large: Asia-Pacific  
 Francisco del Pinal, Member-at-Large: Europe/Africa  
 David Shewring, Member-at-Large: Europe/Africa  
 Jorge Clifton Correa, Member-at-Large: North/Central America  
 Aida Garcia Gomez, Member-at-Large: South America  
 Belinda Smith, Administrative Secretary  
 Rama Sudakar, Administrative Assistant

eZine  
**ifssh**  
CONNECTING OUR GLOBAL HAND SURGERY FAMILY

### IFSSH DISCLAIMER:

The IFSSH ezine is the official mouthpiece of the International Federation of Societies for Surgery of the Hand. The IFSSH does not endorse the commercial advertising in this publication, nor the content or views of the contributors to the publication. Subscription to the IFSSH ezine is free of charge and the ezine is distributed on a quarterly basis.

Should you be interested to advertise in this publication, please contact the Editor:  
[ezine@ifssh.info](mailto:ezine@ifssh.info)

### IFSSH EZINE EDITORIAL TEAM:

**EDITOR:**  
 Professor Ulrich Mennen  
 Past President: IFSSH

**DEPUTY EDITOR:**  
 Professor Michael Tonkin  
 Past President: IFSSH

**GRAPHIC DESIGNER:**  
 Tamrin Hansen  
[www.foxydesign.co.za](http://www.foxydesign.co.za)

**TO SUBSCRIBE GO TO:**  
[www.ifssh.info](http://www.ifssh.info)  
[administration@ifssh.info](mailto:administration@ifssh.info)

# contents



## 4 EDITORIAL

Educational sponsorships, visiting professorships and financial grants  
 - Ulrich Mennen

## 5 PRESIDENT'S MESSAGE

- Dan Nagle

## 6 SECRETARY-GENERAL REPORT

- David Warwick

## 9 IFSSH/IFSHT CONGRESS 2025

## 10 PIONEER PROFILES

• Richard G. Eaton  
 • Yoshikazu Ikuta

## 12 SPECIAL FEATURE

PULPe Webinar on: Constriction Ring Syndrome and Hair Tourniquet Syndrome  
 - Stephane Guero  
 - Nicole Ochsenbein  
 - Daniel Weber  
 - Wiebke Hülsemann  
 - Brid Crowley

## 23 IFSSH SPONSORSHIPS

• IFSSH Educational Sponsorship  
 • Travel Grants and Fellowships

## 31 MEMBER SOCIETY NEWS

- Activities of the Latin American Federation of Hand Surgery 2024-2025
- Indian Society for Surgery of the Hand
- Israeli Society for Surgery of the Hand
- Venezuelan Society of Hand and Reconstructive Surgery of the Upper Limb (SVCMRMS)
- Polish Society for Surgery of the Hand
- Portuguese Society for Surgery of the Hand (SPOCMA)
- Norwegian Society for Surgery of the Hand

## 43 ART

"Hands and Molecule"

## 44 HAND THERAPY

- Exercise Prescription App "Hand Therapy"  
 - Hayley Fay
- IFSHT Newsletter

## 52 SHARE SECTION

- "Hand Surgery Resource" merges with IFSSH
- IFSHT Evelyn Mackin Congress Grant

## 56 UPCOMING EVENTS

## 66 RE-PUBLISHED ARTICLES

Thalidomide review

## Educational sponsorships

# Visiting professorships and financial grants

The International Federation of Societies for Surgery of the Hand (IFSSH) was established in 1966 with its main purpose being to connect colleagues from around the world with an interest in the hand, and to share knowledge and expertise in order to improve the management of hand conditions.

The Federation has grown from the eight founding Societies to the present sixty-three National Member Societies. The IFSSH is also closely associated with the International Federation of Societies for Hand Therapy (IFSHT), and fosters working relationships with regional Hand Federations.

During the first forty odd years, the IFSSH promoted a scientific approach for treating predominantly hand injuries, as well as joint pathologies, congenital anomalies, neoplastic conditions, microsurgical reconstructions and rehabilitation, as stated in its charter.

More recently, due to increased financial capacity of the IFSSH, its purpose has evolved to include a new dimension, namely to support those who do not have the means to join in the academic efforts of the Federation, such as the triennial congresses. Educational sponsorships, visiting professorships and financial grants have been established to enable more participation internationally in acquiring knowledge of hand surgery and therapy.

The Ezine has in the past published a number of reports on successful outreach programmes and educational workshops. This edition again reports on such a worthwhile endeavour by the IFSSH. We sincerely appreciate all the willing colleagues who volunteer and donate their time and expertise freely to spread knowledge to all corners of our planet.

The IFSSH encourages all our members to make use of these generous financial offers. For more information, visit the IFSSH website on: [www.ifssh.info](http://www.ifssh.info)

We wish you a happy and prosperous new year.

Ulrich



**ULRICH MENNEN**

Editor

# President's Message

The IFSSH's Executive Committee is looking forward to a very productive 2024. The new year will kick off with the first Midterm Course to be held in Quito, Ecuador from 31 January to 3 February. The organizing committee, under the leadership of Dr. Fidel Cayón has created an outstanding program and I look forward to participating in this groundbreaking event along with our Immediate Past President Marc Garcia Elias and our Secretary General David Warwick. Please checkout the Course at <https://ifssh.info/pdf/mid-term-course-quito-ecuador.pdf>

This year our Communications Director, Jin Bo Tang in conjunction with Aida Garcia Gomez, the South America Region Member-at-Large, as well as the IFSSH Secretariat will be refining the IFSSH social media presence. This is not a simple process as is evidenced by the many well publicized problems faced by large social media platforms. This subcommittee will develop guidelines during the coming months to promote and guide the exchange of hand surgery knowledge via social media. Please follow our social media posts on "X" and Instagram: @IFSSHHand.

Also, during the coming months you will be hearing about the efforts of your Members-at-large Greg Bain, Jorge Clifton Correa and Paco Pinal to establish a mechanism and program to encourage charitable giving to the IFSSH. Such charitable giving will allow the IFSSH to pursue and expand its global education programs.

The administration of the IFSSH is a daunting task that is executed with aplomb by our very able administrator Belinda Smith. As the breadth of IFSSH activities has expanded it became clear that Ms. Smith would benefit from additional administrative support. Thanks to the efforts of our President-elect



Raja Sabapathy, we have been able to identify and engage the very talented Ms. Rama Sudakar to lighten Belinda's workload. We are delighted Ms. Sudakar has agreed to join the IFSSH team. You will certainly be hearing from her in the future. Welcome Rama!

Finally, while it might seem a bit premature to start talking about the next Triennial Congress, the fact of the matter is I will be seeing you in beautiful Washington DC in less than 15 months. At least I hope to see you; unless of course, you don't take the necessary measures to obtain your United States visa. Not everyone will need a visa, but many will, and the visa application process can be complex and more importantly, time consuming! So, I urge you to go to the United States State Department website to see what you need to do to gain entry into the United States in time to participate in what will be a fantastic congress. (<https://travel.state.gov/content/travel/en/us-visas/tourism-visit.html>)

On behalf of the IFSSH ExCo and IFSSH Secretariat, I wish you a happy, healthy, and prosperous new year.



**DANIEL J. NAGLE**

President: IFSSH

# Message from the Secretary-General



Happy New Year from the IFSSH Executive Committee and Secretariat.

The IFSSH has had a productive 2023 – developing the 2024 Mid Term course, starting planning on the 2025 Congress, growing our secretariat, using social media effectively, giving out grants and creating links for collaboration in outreach programmes. But 2024 will be even more exciting as Dan Nagle describes in the President's Message.

We look forward to Hand Surgeons all over the world getting closer and more engaged in 2024.

As ever, if you have any suggestions for the IFSSH executive Committee or for this Ezine, then please contact your region's Member-at-Large, me, Dan Nagle or the Secretariat and we will always listen.

## 2024 IFSSH Delegates' Council Meeting – Save the date

The 2024 IFSSH Delegates' Council Meeting will be held on Thursday 27th June 2024. This will be in Rotterdam, hosted within the annual FESSH Congress. We hope to see many IFSSH Delegates (or appointed proxies) there to represent the 63 IFSSH member societies.

## 2025 IFSSH Congress – Prepare your bids and nominations

A call for nominations will occur in mid-2024 for multiple items, each to be voted on at the 2025 IFSSH Delegates' Council Meeting in Washington DC.

These include:

- Bids to host the 2031 IFSSH Congress (eligible region: South America - <https://www.ifssh.info/congress-rotation-schedule.php>)
- Bids to host the 2nd IFSSH Mid-Term Course in Hand Surgery – 2026/27 (eligible regions: Europe/Africa or South America - <https://www.ifssh.info/pdf/Mid-Term-Course-Rotation-Schedule.pdf>)
- Nominations for 2025 IFSSH Pioneers for Hand Surgery
- Nominations for the 2025-2028 IFSSH Executive Committee and Nominating Committee positions

Full information will be provided with the official call for nominations in the May newsletter. We hope the IFSSH societies in each eligible region are considering applying to host the future congresses and courses.

## 50th Anniversary - Venezuelan Society for Surgery of the Hand and Reconstruction of the Upper Limb.

The IFSSH sends its congratulations and best wishes to the Venezuelan Society for Surgery of the Hand and Reconstruction of the Upper Limb (Sociedad Venezolana de Cirugía de la Mano y Reconstructiva del Miembro Superior) for the 50th anniversary.

The Venezuelan Society was formed on 11th January 1974 with 9 participants and joined the IFSSH in 1983. The IFSSH is pleased to have honoured a number of members as IFSSH Pioneers of Hand Surgery, including Antonio De Santolo Ricciardelli (2010), Jose Rafael Camarillo Morillo (2016), Rodolfo Contreras Gamboa (2016), Nelson Enrique Socorro Medina (2019) and Maggali Pastora Torrealba Marin (2019).

A reflection on the 50 years has been written by Dr Rodolfo Contreras Gamboa – one of the 1974 founding members – and published in the February 2024 Ezine (Member Society Updates) ([https://ifssh.info/ifssh\\_ezine.php](https://ifssh.info/ifssh_ezine.php)).

## Future Meetings

A detailed list of national and regional hand surgery meetings is available on the IFSSH website. The triennial IFSSH Congresses are as follows:

### XVIth IFSSH – XIIIth IFSHT Congress

Washington D.C., USA  
23rd - 28th March, 2025



### XVIIth IFSSH – IVth IFSHT Congress

Singapore  
23rd – 27th October, 2028



Email: [administration@ifssh.info](mailto:administration@ifssh.info)

Web: [www.ifssh.info](http://www.ifssh.info)

Twitter/Instagram: @IFSSHHand

With best wishes for 2024

David



### DAVID WARWICK

Secretary-General, IFSSH  
[davidwarwick@handsurgery.co.uk](mailto:davidwarwick@handsurgery.co.uk)  
+44 7887 651451

Email: [administration@ifssh.info](mailto:administration@ifssh.info)

Web: [www.ifssh.info](http://www.ifssh.info)

Twitter/Instagram: @IFSSHHand

## DEADLINE EXTENDED: MARCH 15, 2024



# 2025 IFSSH/IFSHT Congress Update

Dear IFSSH/IFSHT Friends and Colleagues,

Here is the latest update for the 2025 IFSSH/IFSHT meeting in Washington DC. The dates are set - from March 23 to March 28, 2025. Check out the new circle logo that will be used for the venue!



This meeting will be hosted by ALL of American Hand Surgery and Therapy; the overall chairs of this meeting are James Chang from the American Society for Surgery of the Hand, David Ruch and Nash Naam from the American Association for Hand Surgery, and Aviva Wolff from the American Society of Hand Therapists.

The meeting hotel will be held at the Marriott Marquis, in the center of Washington DC. The meeting space is on the ground floor of this hotel, making the entire scientific meeting in one setting, which will allow participants to have a central location for all activities. This hotel is fairly new and is within walking distance of the major sites of Washington DC: the Smithsonian Museums, the White House, and the Capitol. In addition to the meeting hotel, we are arranging for overflow rooms at the Renaissance Hotel, across the street as well as for budget lodging in nearby hotels.

Our scientific program chairs, Jeff Yao and Jeff Friedrich are diligently working on the symposia and free paper sessions.

The instructional courses will be organized by Warren Hammert, Fraser Leversedge, and David Ruch. There will be many free papers on a variety of topics. Our goal is to have a truly international list of speakers that will share knowledge from around the world. There will be several joint sessions with the hand therapists from the IFSHT; this will allow attendees to get a truly comprehensive treatment plan for our patients.

The social venues for this meeting should be spectacular. March is cherry blossom season in Washington DC! The major sites, such as the Washington Monument, Lincoln Memorial, Jefferson Memorial, Supreme Court, US Capitol, and White House, are all within walking distance to each other. The Smithsonian Museums, ranging from the National Galleries of Art to the National Air and Space Museum, are always free for all visitors. Therefore, this would be a great meeting for your entire family. The Gala Dinner will be at the National Portrait Gallery. We will be able to view the official portraits of all the US presidents and then dine in the Rotunda in a wonderful setting. This will surely sell out early, so be on the lookout for early-bird registration information.

Please check the website [www.ifssh2025.org](http://www.ifssh2025.org) for continually updated information about the program, registration, lodging, and festivities. All of American hand surgery and therapy are looking forward to welcoming you to Washington DC in March 2025!

The deadline to submit Abstracts for the [IFSSH-IFSHT 2025 Triennial Congress](https://www.ifssh.info/2025), scheduled for March 24-28, 2025, in Washington, DC, USA has been extended to **March 15, 2024**. Submit an abstract to share your expertise with an acclaimed group of international hand surgeons and hand therapists!

Read the important policies and guidelines and submit your Paper, ePoster and Instructional Course Lecture (therapist, only) proposals.

### [SURGEON CALL FOR ABSTRACTS](#)

### [THERAPIST CALL FOR ABSTRACTS](#)

Questions may be directed to [abstracts@ifssh-ifsht2025.org](mailto:abstracts@ifssh-ifsht2025.org).

# Richard G. Eaton

## (1929)



Richard Gillette Eaton was born on 3 December 1929 in Forty Ford, Pennsylvania, USA. He attended the University of Pennsylvania School of Medicine from 1951 to 1955. He did a General Surgery residency at the Peter Bent Brigham Hospital in Boston, Massachusetts, USA. in 1956

and 1957, followed by a Combined Harvard Program residency in Orthopaedic Surgery at the Children's Hospital, Massachusetts General Hospital and Peter Brent Brigham Hospital from 1959 to 1962. Eaton then did a Hand Reconstruction Fellowship with J. William Littler at the Roosevelt Hospital in New York, USA. in 1963, and in 1964 was a Fellow with a NIH Grant for the study of muscle ischaemia. From 1957 to 1959 he served in the Surgical Service of the United States of America Army as a Captain M.C. in Fort Hood, Texas, USA.

Dr. Eaton served as a Consultant Hand Surgeon at the Cape Cod Hospital, Hyannis, Massachusetts from 1956 until his retirement in 2002. In 1986 he was appointed Professor of Clinical Orthopaedic Surgery at the Columbia College of Physicians and Surgeons. From 1988 until 1999 Eaton was the Director of the Hand Surgery Service in the Department of Orthopaedic Surgery at the Roosevelt Hospital in New York.

Richard Eaton was a member of numerous medical organisations, amongst others, American Society of Orthopaedic Surgeons, American Orthopaedic Association, American Society for Surgery of the Hand

(ASSH), American Association for Surgery of the Hand (AASH), American College of Surgeons, New York Society for Surgery of the Hand (President 1980-1981), and Pan-American Medical Association (President 1982-1989). He also served as Associate Editor of the Journal of Hand Surgery (American) (1982-1985) and Associate Editor of Advances in Orthopaedic Surgery (1981-1995). He was Council Member of the ASSH (1974-1977), Founding Chairman of the Clinical Assessment Committee of the AASH (1974-1977), Member of the Membership Committee of the ASSH (1981-1984), Chairman of the Bunnell Fellowship Committee of the ASSH (1988-1991) and Member of the Nominating Committee of the ASSH (1994-1996). He received a Lifetime Achievement Award from the New York Society for Surgery of the Hand.

Richard Eaton published 63 peer reviewed and 8 non-juried review articles, more than 25 book chapters and a classic book on "Joint Injuries of the Hand" (1971) (with illustrations by J.W. Littler). He presented multiple Honorary Lectureships, including the Founders Lecture of the American Society for Surgery of the Hand (1993). His special interests were on the thumb carpo-metacarpal joint, ischaemic muscle contractures, hand joint injuries and the wrist.

Richard was married to Dr. DuRee Hunter Eaton (1931-2010), a Paediatric Radiologist.

At the 11th Congress of the International Federation of Societies for Surgery of the Hand in Seoul, Korea in 2010, Richard G. Eaton was honoured "Pioneer of Hand Surgery"

# Yoshikazu Ikuta

## (1938)



Yoshikazu Ikuta was born on 5 October 1938 in Fukuyama, Japan. He completed his schooling at the Fukuyama High School in March 1957, and graduated as medical doctor from Hiroshima University School of Medicine in 1964. He obtained his post-doctoral degree in

1969 with his thesis titled: "Studies on small vessel anastomosis". Ikuta then did a Fellowship at the Heidelberg University Department of Orthopaedics in Germany. He became a lecturer in the Department of Orthopaedics at the Hiroshima University School of Medicine, was appointed Associate Professor in 1978, and promoted to Professor and Chairman of the Department in 1985. Prof. Ikuta became Director of the Hiroshima University Hospital in 2000, Director of the West Japan Railway Hiroshima General Hospital (2002) and Director of the Hiroshima Hand and Microsurgery Centre in 2007.

In 1976 Yoshikazu was asked to conduct a microsurgery course in Montpellier, France. He was Founding Member of the Japanese Society of Reconstructive Microsurgery and its President in 1976 and from 1999-2001 Chairman of the Board of Directors. He was President of the Japanese Society for Surgery of the Hand in 1994, Chairman of the Board of Directors from 2000 to 2003 and Consultant of the Board from 2005-2008. Ikuta was also President of the Japan Elbow Society (1995), the Asian-Pacific Federation of Societies for Surgery of the Hand (2004), the Central Japan

Society of Orthopaedic Surgery and Traumatology (1995), and Member of the Board of Directors of the Japanese Orthopaedic Association (1999-2001). He was member of numerous national and international Societies and Associations. Prof Ikuta was Editor-in-Chief of the Journal of Hand Surgery (Asian-Pacific) (2003-2009), and served on the editorial board of four peer-review international journals.

Prof. Ikuta is known for his vast experience as a micro-surgeon and his research in microsurgery and tissue survival, survival of tissue transplantation, regeneration of spinal cord injuries and internal and external bone fixation and bone healing. He published extensively on the use of microsurgery, re-attachment of amputated parts and the treatment of hand and finger injuries.

Prof Yoshikazu was honoured with "Pioneer of Hand Surgery" at the 11th International Congress of the International Federation of Societies for Surgery of the Hand in Seoul, Korea in 2010.

## PULPe Webinar on:

# Constriction Ring Syndrome and Hair Tourniquet Syndrome

Constriction ring syndrome is a rare deformation that usually affects multiple extremities of neonates. Hair tourniquet syndrome is an acquired condition in infants that mimics some features of constriction rings. The Paediatric Upper Limb Project Europe (PULPe) held a webinar on these subjects in April 2023. The moderators were Daniel Weber (Switzerland) and Brid Crowley (Ireland). The aims of the webinar were to give an update on the etiology, prenatal and postnatal treatment options and to provide a platform to discuss challenges.

Our invited international experts gave the following talks:

### Constriction Ring Syndrome:

Embryology and Etiology

- Stéphane Guéro, France

Antenatal management and fetoscopic interventions

- Nicole Ochsenbein, Switzerland

Primary reconstructions

- Daniel Weber, Switzerland

Secondary reconstructions

- Wiebke Hülsemann, Germany

### Hair Tourniquet Syndrome:

Management

- Bríd Crowley

The Webinar can be re-viewed on the PULPe homepage [www.PULPe.eu](http://www.PULPe.eu) (you need to register to have access to all videos – it's free of charge)

## 1. CONSTRICTION RING SYNDROME

### 1.1 The etiology of constriction rings:

**Stéphane Guéro**

#### Q: Is the etiology of constriction ring syndrome known?

Currently not. There are two theories, the extrinsic and the intrinsic. The extrinsic theory assumes that after early amniotic disruption amniotic bands constrict the finger and result in disruption ranging from constriction rings up to complete amputation. If it happens very early, before 56th day after fertilization, compromising normal hand plate formation, finger growth and ray separation are affected.

This theory supports the finding of remnants of amniotic membrane sometimes found in the constriction ring in the newborn (Scheijgrond, Rodrigues Pereira et al. 1989). The intrinsic theory advocates vascular disruption, which can explain associated anomalies of deep organs like in the lungs and intestines.

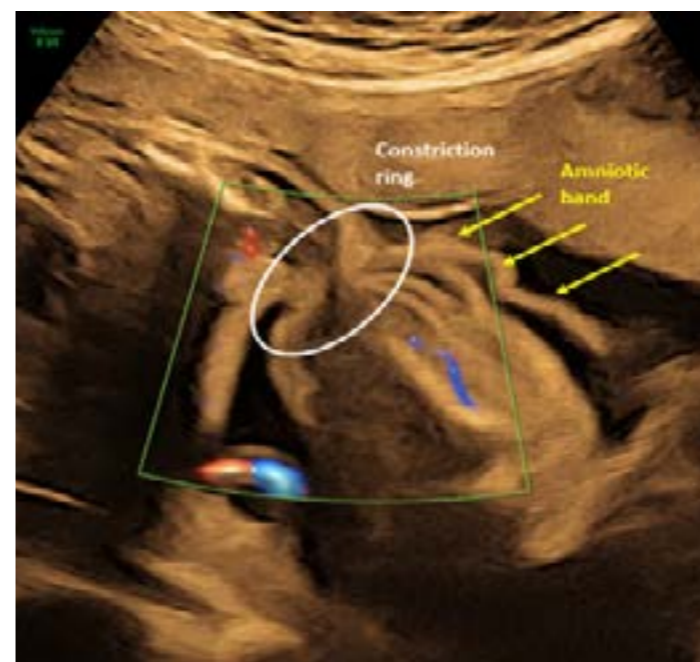
#### Q: Are there any associated anomalies?

Yes. Lung hypoplasia, lymphangioma, aplasia cutis, and tibial pseudarthrosis can be associated with constriction ring syndrome. This supports the intrinsic theory of Streeter. Eventual lymphoedema and stripes of the face can be part of the disease.

### 1.2. Prenatal diagnosis and management of constriction rings: Nicole Ochsenbein

#### Q: What are prenatal treatment options for constriction rings?

The challenge of prenatal treatment is antenatal detection of the constriction rings. Diagnosis should take place before devastating amputations occur. Standard pregnancies are screened by ultrasound around 11-13 weeks and 18-22 weeks and therefore they often miss critical constrictions. If constriction rings are detected, prenatal interventions can be considered after 16 gestational weeks (Gueneuc, Chalouhi et al. 2019).



**Fig 1: Antenatal detection of constriction ring on an upper arm in prenatal ultrasound (Courtesy: Nicole Ochsenbein, Department of Obstetrics, University Hospital Zurich)**

Fetoscopy allows access to the child and the lesion can be visualized through the 3mm trocars. The intervention includes an incision of the bands with laser, scissors or blunt dissection and has a success rate up to 75% (Gueneuc, Chalouhi et al. 2019). Successful interventions improve vascularization of the limb and prevent further deterioration. However, postnatal follow-up is needed and further interventions are often necessary.

#### Q: What are the risks of these prenatal interventions?

There are two risk categories: fetoscopic interventions can induce preterm labor and birth in up to 40% of all interventions. If this occurs before approximately 24 weeks of gestation, survival of the fetus is at risk, whereas at a later gestational age, the complications of preterm delivery must be anticipated. Furthermore, there are risks by the actual intervention: The limb can be severed with the manipulation and success cannot be guaranteed. These potentially devastating complications explain, that potential benefits must be weighed against the risks and antenatal interventions are therefore being considered only in severe constrictions bands ( $\geq$  stage 2) in which whole limbs or hands could be amputated (Husler, Wilson et al. 2009). Mild constrictions (stage 1) or constriction rings that affect only fingers or a part of a hand are currently not considered as indications for prenatal interventions.

#### Q: What are your recommendations regarding prenatal counselling?

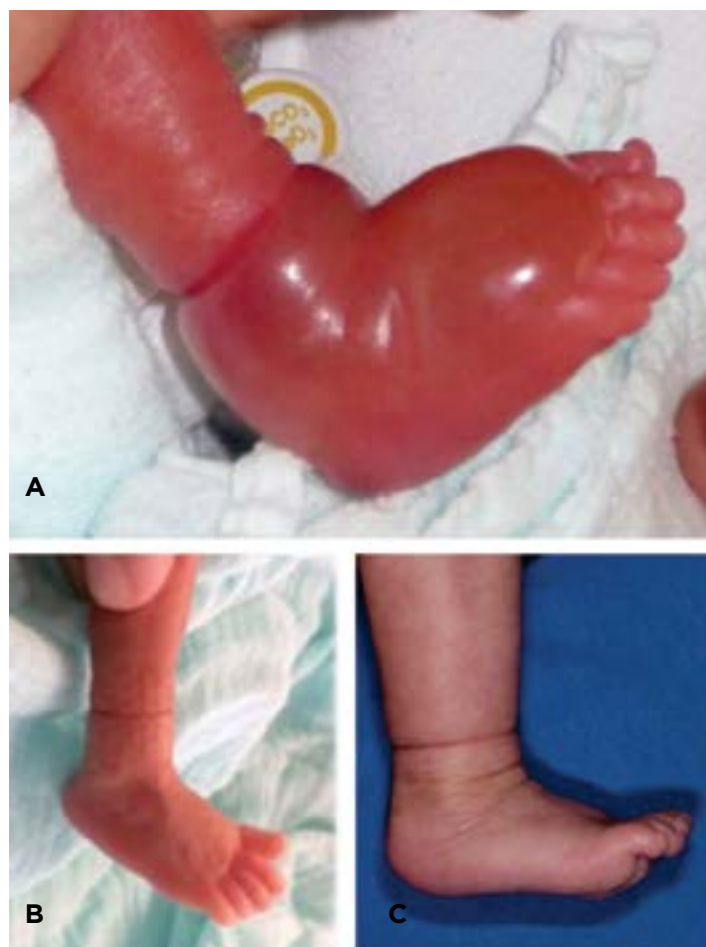The vast majority of antenatally detected constriction rings are not being treated by prenatal intervention. However the diagnosis is always a big burden to the parents. They benefit greatly from prenatal counselling by pediatric hand surgeons and teams who can explain the treatment options. It is also important to give them reassurance, that most children with isolated hand or foot deformities develop an age appropriate autonomy and achieve a high health related quality of life, which is similar to the normal population.

Ideally, the prenatal counselling should be provided by pediatric hand surgeons and obstetricians in a combined setting.

### 1.3. Primary interventions for constriction rings: Daniel Weber

#### Q: What are the indications and techniques for surgery for constriction rings in children?

Primary interventions for constriction rings have three main indications with specific urgencies:



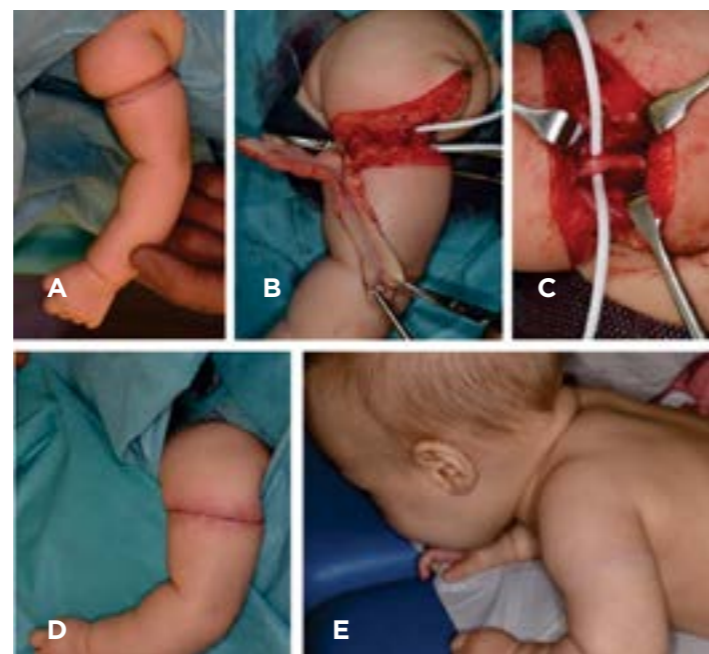
**Fig. 2 A:** Massive edema and hypoperfusion of toes in a preterm neonate at birth. **B:** Quick recovery of oedema after longitudinal incision of the ring as a bedside procedure (courtesy of Simona Imhof, Neonatology, University Hospital Zurich). **C:** Unimpaired function of the foot at 6 months of age (courtesy Daniel Weber, University Children's Hospital Zurich).

#### 1. Prevention of progressive soft tissue loss at birth

Deep constriction rings that endanger the vascularity of affected tissues at birth are rare.

They may be located in the lower leg (figure 2), the humerus or digits.

Immediate interventions are needed in these unusual cases with insufficient recapillarisation or oxygen saturation. Affected neonates, sometimes preterm, can have unstable vital parameters. A longitudinal incision of the constriction ring can be performed as a bedside emergency procedure in these cases.



**Fig. 3 A:** Circular incisions must be planned at considerable distance from and parallel to the constriction ring, in an area where the extremity has a normal diameter.

**B, C:** Neurovascular structures must be identified and a formal neurolysis performed in cases with neuromotor deficits.

**D:** Skin closures can be circular without Z-plasties. **E:** Follow-up at 6 months (courtesy Daniel Weber, University Children's Hospital Zurich).

#### 2. Prevention of progressive nerve injuries

Constriction rings of arms or legs can be very deep although vascularization of the limb may still be sufficient. The affected hand or foot can be hypotrophic and associated with peripheral sensation and motor deficits.

Although uncommon, these possibly progressive deficits should be detected and resection of rings with neurolysis should be considered within the first weeks to months of life (figure 3).

#### 3. Prevention of progressive edema with soft tissue proliferations

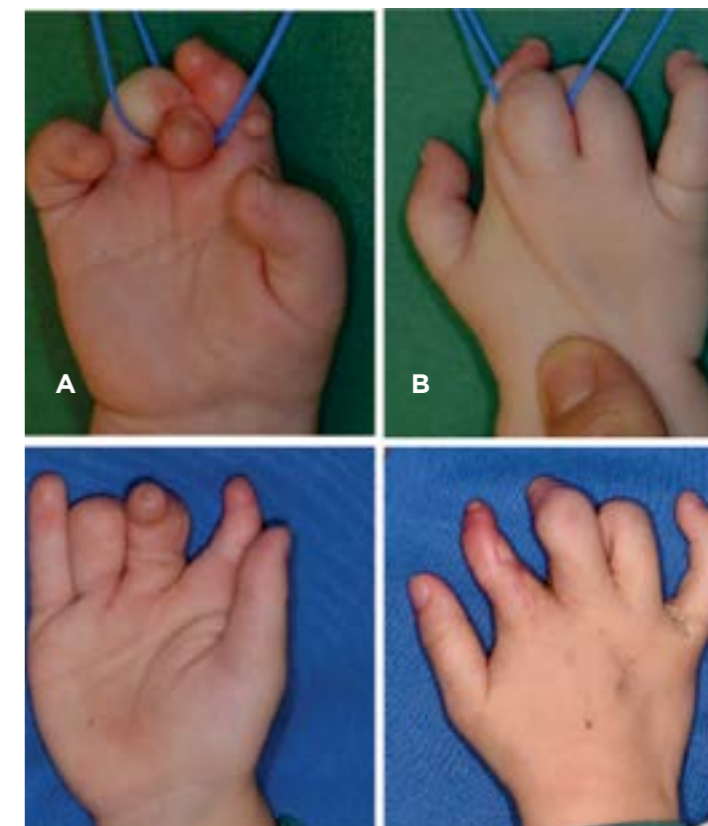
Many rings affect the venous and lymphatic drainage without compromising the arterial blood supply. Edema of the affected hand, foot or digit can be considerable and progressive. A non-reversible soft tissue proliferation can be observed if the ring is not surgically released.

Circular resection and generous soft tissue mobilization follow the principles as mentioned above. These interventions are often performed at 6-18 months of age.

#### 4. Separation of syndactylies

Apical syndactyly (acro-syndactyly) is a characteristic of ring constriction syndrome: A normal hand was formed at an early development with secondary amputations due to the constriction rings, often associated with distal fusion of the digits (figure 4).

Fusions due to the constriction rings can be very tight and fingers may overlap or cross each other. Release within the first months can be considered in these severe cases. Although principles of release follow those in other syndactylies, the soft tissue coverage of the fingertips is often poor. Primary slight shortening of the apical bone should be considered in these cases.

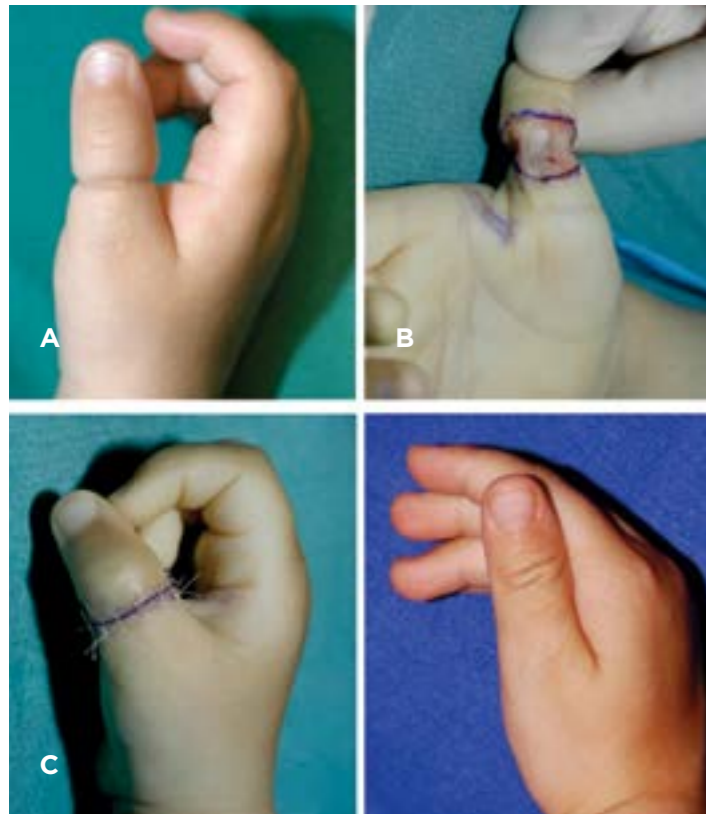


**Fig. 4 A, B:** Constriction rings can amputate distal phalanges and fuse the affected digits simultaneously. Nevertheless the web spaces may be preserved (demonstrated in the photograph with vessel loops). Postoperative results after separation are often moderate due to instability of the affected, hypoplastic interphalangeal joints and poor soft tissue coverage (courtesy Daniel Weber, University Children's Hospital Zurich).

#### 5. Improvement of aesthetics

Some patients or parents dislike the appearance of constriction rings, although they impair neither function nor development. It is imperative to aim for an optimal aesthetic result if one attempts to correct these superficial rings surgically. Therefore, zigzag plasties should be avoided. This surgery can be performed together with other surgical procedures if needed or at a later age, ideally if the child herself or himself asks for correction.





**Fig. 5 A: Superficial constriction ring without functional impairment. B: Surgical correction. C: Late follow-up (courtesy Daniel Weber, University Children's Hospital Zurich).**

**Q: What's your preferred technique to excise constriction rings?**

The goal of the surgery is to excise the constriction ring and to readapt the soft tissue cover. In the vast majority of cases, the incisions can be circular without a need for additional Z-plasties for skin closure. It is essential however, to do a generous soft tissue release with resection of the fibrotic deep ring to prevent recurrence (figure 3). The fascia of the muscular compartments must be released with longitudinal incisions if arms or legs are involved. Against traditional teaching, circular scars tend to grow with the child without causing secondary constrictions in the long time follow-up, if initial skin excision and soft tissue mobilization are adequate (Habenicht, Hulsemann et al. 2013).

One stage circumferential excision of constriction rings is usually feasible and not associated with higher complications than a staged release. However, one should always be able to detect neurovascular structures when doing so, otherwise a two-stage procedure is worth considering (Prasetyono and Sitorus 2015)

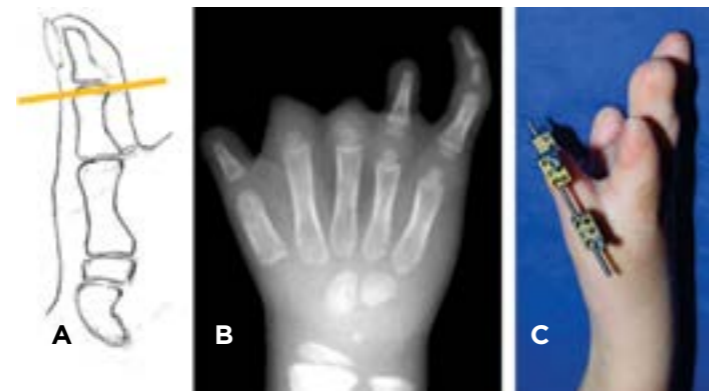
**1.4. Which secondary reconstruction can improve affected hands? Wiebke Hülsemann**

Primary surgical procedures aim to reduce further loss of tissue and function, whereas secondary reconstructions aim to reconstruct function and appearance.

**Q: What are the surgical options for thumb reconstructions?**

Lengthening of the thumb is essential to grasp larger objects, particularly if multiple fingers are affected by amputations. Various techniques help to improve prehension by thumb reconstruction. Choice of procedure depends on the level of amputation, the availability of toes and parental choice:

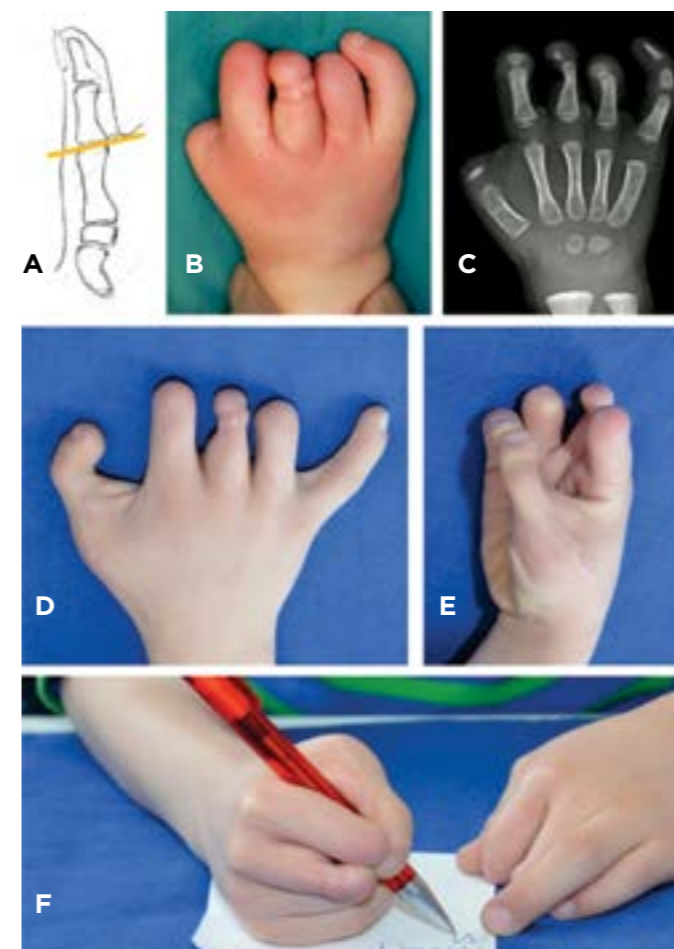
- **A: Amputation at IP level of the thumb:** Lengthening of the thumb's proximal phalanx by callus distraction is recommended. Good soft tissue coverage of the stump and sufficient length for installing the distraction device are a prerequisite.



**Fig. 6 A: Thumb amputation at the IP level can be suitable for callus distraction.**

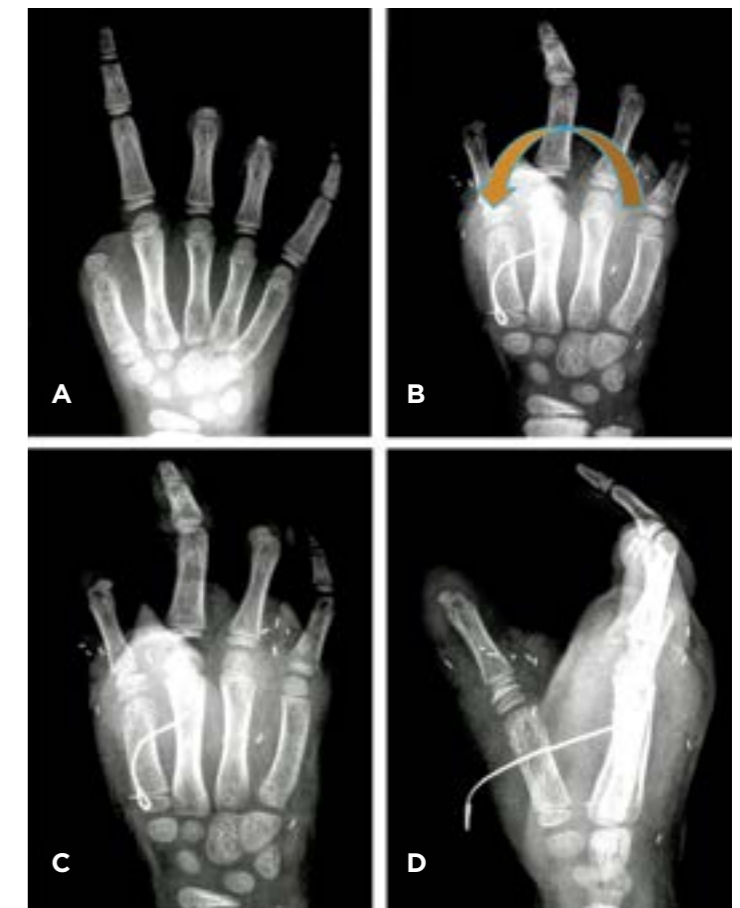**Fig. 6 B: preoperative X-ray. C: Lengthening of the proximal phalanx of the thumb with external distractor (courtesy Wiebke Hulsemann, Children's Hospital Wilhelmstift, Hamburg).**

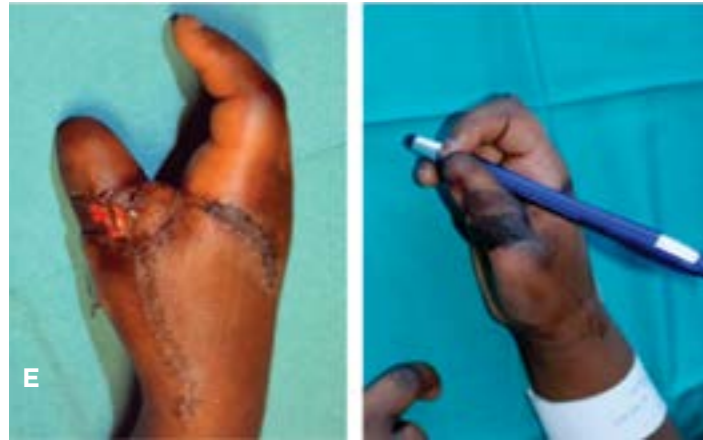- **B: Amputation at MCP level:** Free microvascular toe-to-hand transfer is recommended. Distraction lengthening of the first metacarpal does not provide enough length for a functional thumb. Besides, we would just create a stiff long thumb without mobile joints beyond the CMC. The structures proximal to the constriction ring are always normal and provide a good base for a toe transfer. Nevertheless, we had more postoperative problems with the arterial blood supply in toe-to-hand transfers for constriction rings than for other malformations. Absence of thumb at MCP level is associated with a narrow first web which requires widening at the time of toe transfer (Foucher, Medina et al. 2001).



**Fig. 7 A: Thumb amputations at the MCP level may be suitable for toe to hand transfers. B, C: Preoperative X-ray and photograph. D, E, F: Postoperative result: At 3 yrs. of age, a toe-to-hand transfer with the second toe was performed. The boy had a very functional thumb with a powerful pinch at the 5-year follow-up. He remained right handed, despite having a normal thumb on the other hand (courtesy Wiebke Hulsemann, Children's Hospital Wilhelmstift, Hamburg).**

- **C: Amputation at the MCP level without available toes for microsurgical transfers:** Sometimes, toes are partially amputated or missing, or parents do not want a toe transfer. Thumb reconstruction by transposition of the least functional finger to the remnant of the thumb is recommended. Transposition is performed on the finger's palmar neurovascular bundle with microsurgical reconstruction of a dorsal vein and widening of the first web e.g. by a rotational advancement flap.





**Fig. 8 A: preoperative X-ray. B: Principle of transfer of the ring finger on top of the first metacarpal. C,D,E: Early postoperative X-Rays and clinical result. E. Now the child can grasp the glass with one hand and write easily (courtesy Wiebke Huelsemann, Children's Hospital Wilhelmstift, Hamburg).**

**Q: What are the principles of finger reconstructions?**

Similar distractions can be performed in finger amputations at the PIP level. The finger can be lengthened but remains altered because of no nail. The distracted finger is stiff due to lack of joints. This limits improvement in function.

In more proximal amputation a missing finger can be principally reconstructed by microvascular toe transfers. The best indication is presence of a thumb with amputation of all 4 fingers. Toe transfer creates a partner digit for the thumb.

Free phalangeal transfers are not recommended because soft tissue coverage is usually insufficient to accommodate a free phalanx.

**Q: What's your approach to painful stumps after partial amputation?**

With growth, the bony end of the amputated finger can push against the covering skin causing pain. In extension, the thin skin layer of the stump blanches. Treatment is simple: the phalanx needs to be shortened.

**Q: Teenagers with constriction rings and amputated fingers tend to complain about the appearance of their hands. What's your advice in this age group?**

Most teenagers and adolescents adapt well to their hand with little functional impairment in their daily lives. However, their expectations regarding aesthetics are very high and are often not met by surgical reconstructions. Psychological counselling may support these individuals to better accept the special appearance of their hands. Cosmetic partial hand prostheses are an option for certain situations with social contacts, e.g. disco visits. The teenagers need to know that sensitivity is lost when wearing the prosthesis and function is impaired.

Waters PM, Bae DS. Pediatric hand and upper limb surgery: a practical guide. Lippincott Williams and Wilkins Philadelphia 2012: 85-89

## 2. HAIR TOURNIQUET SYNDROME

### 2.1 What is Hair Tourniquet Syndrome?

- Bríd Crowley

Hair or fibre wraps around an appendage creating a tourniquet like effect. This gives rise to pain, swelling, distal oedema, vascular compromise. In toes, hair is the most frequent cause. In fingers, fibres/threads from clothing are the most frequent cause.

**Q: What is the first line treatment at the emergency ward?**

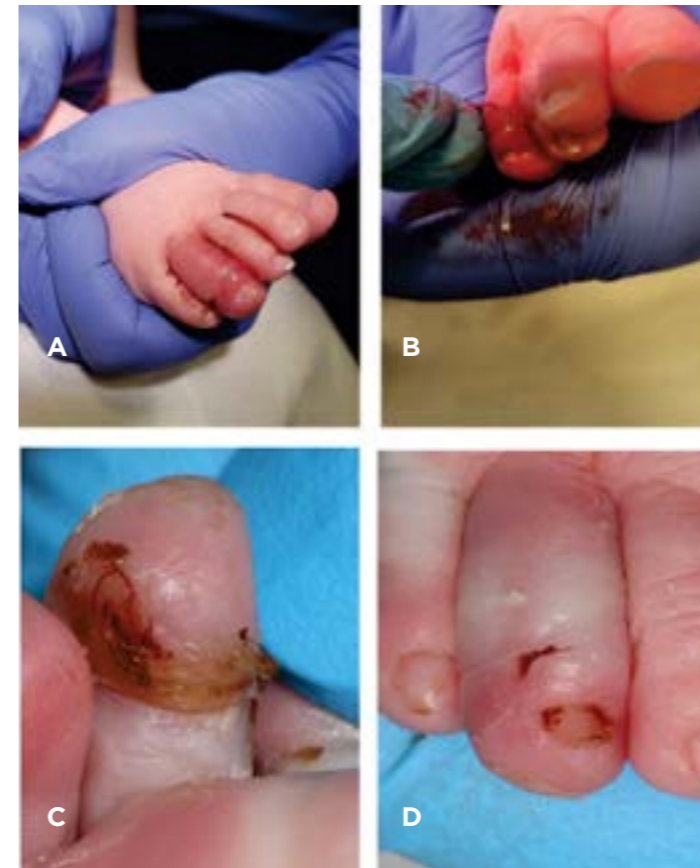Attempt to remove the hair or thread. This should be undertaken in a calm environment with the child securely held e.g. wrapped in a blanket and with an assistant to hold the affected appendage. Good light, loupe magnification and fine instruments are recommended. A blunt probe can be used to pass beneath the hair or fibre.

The hair or fibre can be uncoiled or it can be cut. A variety of cutting devices may be used including scalpel, micro scissors, suture cutting blade, suture needle (cutting type).

Hair removal cream is a treatment option for constriction caused by hair. This is sometimes successful when used in isolation or it may be an adjunct to mechanical removal of hair. Hair removal cream will not work if the constriction is caused by fibre or thread.

Check for the presence of multiple hairs or fibres. (Golshevsky, Chuen et al. 2005, Mat Saad, Purcell et al. 2006)

**Q: What do you recommend if initial treatment is not successful?**



**Fig. 9: Hair tourniquet syndrome A: Presentation at emergency ward, B: Removal of hair, C, D: Recovery (courtesy Bríd Crowley, Great North Children's Hospital, Newcastle upon Tyne).**

Formal exploration should be undertaken under general or local anesthesia or sedation. Longitudinal mid lateral incisions down to bone should be made to ensure division of the constricting material. Debridement of devitalized tissue should be undertaken. Post-operative management with dressing care and topical antiseptic ointment will usually achieve healing.

**Take-home messages for Hair Tourniquet Syndrome:**

Formal exploration should be undertaken under general or local anesthesia or sedation. Longitudinal mid lateral incisions down to bone should be made to ensure division of the constricting material. Debridement of devitalized tissue should be undertaken. Post-operative management with dressing care and topical antiseptic ointment will usually achieve healing.

## REFERENCES:

Foucher, G., et al. (2001). "Toe transfer in congenital hand malformations." *J Reconstr Microsurg* 17(1): 1-7. Fifty-eight patients with congenital hand abnormalities underwent 65 toe-to-hand transfers. Symbrachydactyly (51 cases) was the most frequent indication. Forty-seven second toe-to-hand transfers were performed in 44 patients. The mean follow-up time was 5.2 years. Two failures occurred in cases in which only one artery was anastomosed; no failures were noted when more than one artery fed the transfer. Two patients with a single second-toe transfer presented with lateral instability of the transferred metatarsophalangeal joint. The mean active range of motion was 38 degrees, with a mean extension lag of 25 degrees. The mean two-point discrimination was 5 mm. Forty-one patients used the transferred toe well, when performing activities of daily living and playing games. Toe-to-hand transfer, prior to the establishment of the grip pattern, facilitates integration of the transfer.

Golshevsky, J., et al. (2005). "Hair-thread tourniquet syndrome." *J Paediatr Child Health* 41(3): 154-155. We report a case of hair-thread tourniquet syndrome involving the labia majora of a 14-year-old autistic child. 'Hair-thread tourniquet' refers to the process whereby a thread of hair leads to the ischaemic strangulation of an appendage or other piece of tissue. Uncommonly recognized, this syndrome has gradually gained recognition since its first description in 1612. As it remains infrequent, many have attributed its aetiology to abuse or socio-cultural practices. We review the published literature on this infrequent but important paediatric condition.

Gueneuc, A., et al. (2019). "Fetoscopic Release of Amniotic Bands Causing Limb Constriction: Case Series and Review of the Literature." *Fetal Diagn Ther* 46(4): 246-256.

The aim of this study was to review the perioperative complication rates and neonatal outcomes after fetoscopic release of amniotic bands that caused bilateral limb constrictions. We present 5 cases of limb constriction by amniotic bands occurring spontaneously or following fetoscopic surgery and also include a review of 21 previously published cases. The cases were analyzed for indication, surgical technique, and postoperative follow-up. In our population and the literature, the majority of the children acquired a functional limb (75%), with few perioperative complications (15%). Fetal morbidity was mainly linked to the consequences of preterm premature rupture of the membranes (38.4%) and preterm birth (34.7 GW). The mortality rate was low (7.7%). This review only describes amniotic bands causing limb constriction, and illustrates that fetoscopic surgery for their release is technically feasible with an acceptable perioperative complication rate. However, the 75% success rate is very likely to be an overestimation of the true success rate. In view of these observations we cannot recommend treatment for cases where the fetus has been extensively affected by the bands. We believe, however, that we could consider this technique for a fraction of amniotic band syndrome cases isolated to the limb

constrictions. This kind of surgery should be proposed as a potential treatment for amniotic band syndrome.

Habenicht, R., et al. (2013). "Ten-year experience with one-step correction of constriction rings by complete circular resection and linear circumferential skin closure." *J Plast Reconstr Aesthet Surg* 66(8): 1117-1122. BACKGROUND: In amniotic band syndrome (ABS) constriction rings affecting the limbs are regularly seen at birth. Circular resection and closure with multiple Z-plasties has been described as the treatment of choice. However, direct circular closure creating linear circumferential scars might replace multiple Z- or W-plasties to reduce scars and improve aesthetic outcome. METHODS: From 2000 to 2009 we treated 160 patients with ABS. In 43 cases release of isolated constriction rings was performed by circular excision and closure. Constriction rings were completely resected and skin closure could be performed without Z-plasty in all cases. Data from follow-up of all cases were reviewed and photographs and recordings reassessed. The median age at operation was 14.3 months (range 2-32). Constriction rings were localised on the upper arm in five patients, the lower arm in five, the wrist in two and at the metacarpal level in five. At the lower extremity the thigh was affected in three and the lower leg in 23 patients. RESULTS: In the 16 cases of the first treatment period from 2000 to 2004, average follow-up was 6.5 years (range 5.1-10.3). We observed two minor complications following 43 operations (wound dehiscence and secondary healing). No formation recurrence of banding was seen. Aesthetic outcome was overall good. CONCLUSIONS: We found excellent aesthetic and functional results following change of treatment from multiple Z-plasties to linear circumferential closure. Scars were generally less noticeable and no recurrence or scar constriction could be detected with growth. However, radical excision of all constricting tissues prior to wound closure is mandatory.

Husler, M. R., et al. (2009). "When is fetoscopic release of amniotic bands indicated? Review of outcome of cases

treated in utero and selection criteria for fetal surgery." *Prenat Diagn* 29(5): 457-463.

OBJECTIVES: The objectives are to analyze the outcomes of fetal interventions for fetal limb abnormalities associated with amniotic band syndrome (ABS), to compare the outcome with the known natural history, and to establish selection criteria for fetal intervention. MATERIAL AND METHODS: In a Medline search, six cases of prenatal fetoscopic interventions for ABS were found. An unpublished case was added. RESULTS: Review of the seven cases of treated ABS in utero suggests that abnormal, but present blood flow at Doppler distal to the area constricted by the band may optimally identify cases suitable for fetal surgery. We propose a prenatal classification in stages of cases of ABS based on ultrasound and Doppler findings. Premature rupture of membranes (PROM) occurred in five patients (71%). The median gestational age (GA) at delivery was 34.8 weeks (range 32 to 39). The median time between procedure and PROM was 6 weeks (range 4 days to 14.3 weeks). The median time between procedure and delivery was 11.8 weeks (range 5-17). CONCLUSION: The use of a uniform prenatal classification of cases of ABS may allow a more precise correlation of prenatal findings and postnatal outcome.

Mat Saad, A. Z., et al. (2006). "Hair-thread tourniquet syndrome in an infant with bony erosion: a case report, literature review, and meta-analysis." *Ann Plast Surg* 57(4): 447-452.

Hair-thread tourniquet syndrome is a rare condition where appendages are strangulated by an encircling strand of hair, a thread, or a fiber. The condition usually occurs in very young patients in the first few months of life. We present a unique case of a 3-month-old baby girl with hair-thread tourniquet syndrome in whom a hair cheese-wired through the skin and soft tissue of the toe and caused bony erosion of the underlying phalanx. An extensive literature review and meta-analysis of the topic are also presented.

Prasetyono, T. O. and A. S. Sitorus (2015). "A review on the safety of one-stage circumferential ring constriction

release." *Int Surg* 100(2): 341-349.

The study was undertaken to investigate the use of one-stage circumferential ring-constriction release with Z-plasties regarding the safety, aesthetic appearance, and limb function. A thorough review was conducted on all English publications in PubMed during the period of 2001 through 2011. Titles and abstracts were identified using online search engine from National Library of Medicine's PubMed database under the keywords "limb constriction ring," "limb constriction band," "amniotic band," "annular constriction," and "circumferential constriction." We used Boolean operator and field of title. Evaluation was done to search indications, timing of the first surgical intervention, time interval between surgeries, patients' gender, anatomic location of the ring, wound healing problems, and scar quality. Fourteen publications met the criteria. There were 17 patients with 25 ring constrictions in total. Sixteen ring constrictions (64%) were circumferential; nine (36%) were semi-circumferential. Mean age of 14 patients treated with one-stage release was 4.8 years. Six articles mentioned about normal development of postoperative limb function. Mean age of three patients treated with staged release was 10.5 months. Two articles mentioned regained distal muscle function postoperatively. It is confirmed that surgeons may continue the practice to release circumferential CRS in one stage.

Scheijgrond, W. J., et al. (1989). "[Early amnion rupture as a cause of multiple congenital abnormalities in the newborn infant]." *Tijdschr Kindergeneesk* 57(2): 58-60. We describe two children with congenital deformities due to the early amniotic rupture syndrome. One child who had an amniotic band around the upper arm suffered from a distal nerve lesion. This was relieved following surgery. The second child died shortly after birth of multiple congenital malformations. The most usual findings in this syndrome are constriction of a limb by an amniotic band, scoliosis or syndactyly due to oligohydramnion with compression. We discuss one accepted hypothesis (subscribed by an experimental animal study) of the aetiology of the early amniotic rupture syndrome.

## AUTHORS:

**STEPHANE GUERO**[sguero2@gmail.com](mailto:sguero2@gmail.com)

Institut de la Main, Paris, France

**NICOLE OCHSENBEIN**[Nicole.Ochsenbein@usz.ch](mailto:Nicole.Ochsenbein@usz.ch)Department of Obstetrics  
University Hospital Zurich  
Rämistr. 100, 8006 Zurich, Switzerland**DANIEL WEBER**[Daniel.Weber@kispi.uzh.ch](mailto:Daniel.Weber@kispi.uzh.ch)Division of Hand Surgery  
University Children's Hospital Zurich  
Steinwiesstr. 75  
8032 Zurich, Switzerland**WIEBKE HÜLSEMANN, MD**[wiebke.huelsemann@t-online.de](mailto:wiebke.huelsemann@t-online.de)Handsurgery Department  
Children's Hospital Wilhelmstift  
Liliencronstraße 130  
22149 Hamburg, Germany**BRID CROWLEY**[b.crowley@nhs.net](mailto:b.crowley@nhs.net)Consultant Plastic and Hand Surgeon  
Great North Children's Hospital  
The Newcastle upon Tyne Hospitals NHS Foundation  
Trust  
Newcastle upon Tyne NE1 4LP, UK  
(FESSH delegate Irish Hand Surgery Society)  
22149 Hamburg, Germany

# IFSSH Educational Sponsorship

## KLEINERT VISITING PROFESSORSHIP 2023: POLAND

**EDITOR'S NOTE: DR JIN BO TANG VISITED POLAND AS THE IFSSH KLEINERT VISITING PROFESSOR FROM 17 SEPTEMBER TO 2 OCTOBER 2023. THE FULL REPORT IS AVAILABLE ON THE IFSSH WEBSITE: [WWW.IFSSH.INFO](http://WWW.IFSSH.INFO)**

This was an extraordinarily well-organized visiting professorship by the Polish Society for Surgery of the Hand and sponsored by the IFSSH. It is difficult to describe how excellent the teaching contents, the arrangement in 6 cities and the transportation were and how much the educational mission has achieved with this trip. I also found that I cannot describe in words the hospitality, kindness, warmth, and closeness of all the involved colleagues and hosts during my 16 day visit across Poland. In summary, this visiting professorship included 25 lectures, 23 delivered in labs or hospital auditoriums in 5 cities, and 2 at the National Congress. We also had 10 workshops (cadaveric workshops, practical training workshops using simulations, and young scientists workshops) in 10 days, clinical patients examination with case discussion in 4 cities, and operations on 10 patients in 4 days, as well as numerous personal discussions (every day), questions and answers (every day), consultations, and many social events at the National Congress, participating in the university parade and the inauguration of the new academic year by invitation from the medical university dean, and some other culture events.

The colleagues of the Polish Society were extremely dedicated and supportive. They had spent a lot of time, many online video calls and phone calls to coordinate

the program months ahead of my visit. In all cities, my hotel was arranged at a location close to the town centre and in hotels with a Polish character, which allowed me to experience these Polish cities during a short and busy stay in each city. Clearly this was their well-coordinated decision in the planning. The ratio of talks, operations, demonstration, and short guided tours was almost the same in all the cities, all very carefully planned.

In almost all of my lectures I included a photo of Dr Kleinert and labeled the talk as "IFSSH Kleinert Visiting Professorship". I explained that Dr Kleinert was a pioneer, a surgeon, a giant and a teacher. Now his legacy is passed on to the next generations and his spirit of teaching and education is carried out in the form of inviting a senior hand surgeon every year to educate and share knowledge with colleagues in different countries. A Chinese saying states that a great teacher should "never be tired of teaching" if one is entitled to teach and has something worthwhile to teach. This is exactly what the central goal and mission of IFSSH is: education.

Physically it was tiring, but the spirit of the mission kept me going forward, and I have never tired spiritually. I feel enriched by building ties and friendships with so many colleagues.

I can feel the warmth, kindness, and keenness even now while I am writing this report. This visit was a privilege and an experience I will cherish all my life. My wish is that education and collegial friendship will keep our IFSSH family close.

**JIN BO TANG**

## IFSSH HAROLD KLEINERT VISITING PROFESSORSHIP 2023

### Meeting Professor Jin Bo Tang: A Special Time for Polish Hand Surgeons

Thanks to the generous funding from the IFSSH, the realm of the Polish Hand Surgery Society witnessed a truly remarkable event, as surgeons and enthusiasts alike seized the extraordinary chance to connect with and learn from the esteemed Professor Jin Bo Tang. Arriving in our country on the 17th of September 2023 for a fortnight, the Professor embarked on an educational journey, gracing six academic centres and cities with his expertise.

Prof Jin Bo Tang, a luminary in tendon surgery and the treatment of hand trauma, brought with him a wealth of knowledge and experience. His influence extends globally, with numerous publications, ground-breaking techniques, and a philosophy that resonates across the field of treatment.

The primary goal of this visit was to elevate the standards of treatment and knowledge among resident doctors and specialists engaged in hand surgery across our country. This initiative spanned not only academic hubs but also smaller, non-academic hospitals.

Our crafted program featured a rich tapestry of lectures, seminars, and hands-on courses employing models and human specimens in selected units. We also integrated participation and lectures into our national biannual meeting of Polish Hand Society Congress, ensuring a targeted approach that left a lasting impact on a significant number of surgeons.

Commencing on the 17th of September 2023 in Poznan (local host: Piotr Czarnecki): Prof Tang was warmly welcomed at the airport by President of Polish Society, Paweł Zejler and local host, Piotr Czarnecki. The three-day visit was filled with a two-day cadaver course with lectures and practical demonstrations (Figure1),

hospital visits in Traumatology, Orthopaedics and Hand Surgery Department (Figure 2), collaborative case discussions and working together in the operating room (Figure 3), and honorary lectures for the Department and members of the local division of the Polish Orthopaedics Society. Prof Tang's free time was filled with a guided Poznan tour and evening socializing in the city.

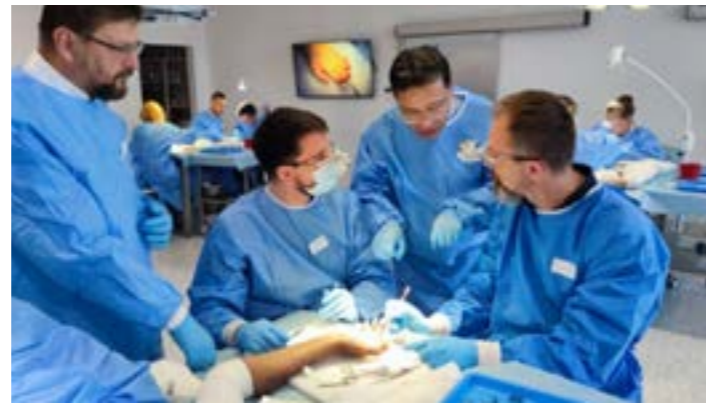

Fig. 1: Prof Tang at the cadaver lab, Poznan.



Fig. 2: The Orthopaedic Clinic team

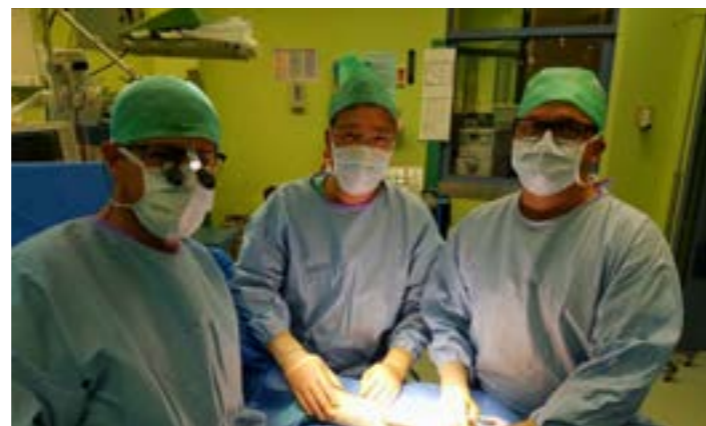

Fig. 3: Prof Tang in the Operating Room

Moving to Lodz (local host: Robert Rokicki) on the 20th of September 2023, the momentum continued with a two-day stint featuring visits to the Hand Department (Figures 4 and 5), lively case discussions, surgery demonstrations, and lectures for the local Orthopaedic society, concluding with a convivial dinner.



Fig. 4-5: Prof Tang with patients at the Lodz Hand Surgery Clinic

The tour then took on the vibrant backdrop of Warsaw (local host: Maciej Klich), our capital, on the 23rd of September 2023. The main event here was an engaging course on human specimens, replete with practical activities and lectures on tendon repair and rehabilitation (Figures 6 and 7). The participants - a mix of hand surgeons and therapists - enjoyed both professional insights and a bit of leisure, with time allocated for sightseeing and a delightful dinner with the national faculty.



Fig. 6: Course participants, Warsaw

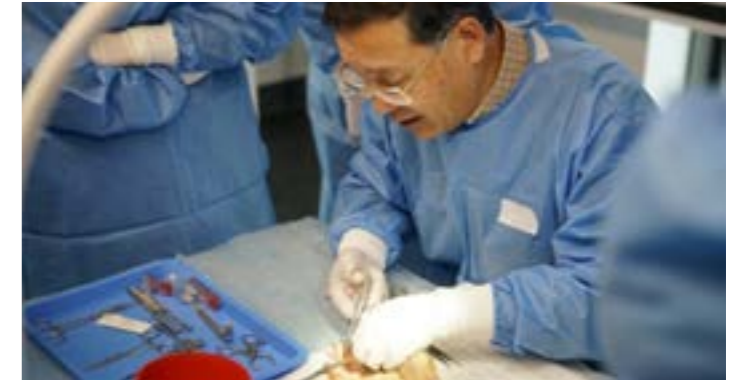

Fig. 7: Prof Tang demonstrating techniques

Wroclaw (local host Paweł Reichert), another academic hub, hosted the visit from the 24th of September 2023 for three days, featuring a dynamic program in the Department of Orthopaedic, Traumatology and Hand Surgery. Highlights included a Hand Surgery and Reconstructive Surgery Course for residents, live surgery, and lectures for doctors and residents, all capped off with a splendid gala dinner. (Figures 8 & 9)



Fig. 8 and 9: Prof Tang with Wroclaw course participants

Between the 28th and 30th of September, the Congress of the Polish Society for Surgery of the Hand unfolded in Czestochowa (local host: Paweł Zajler). It proved to be a high-energy gathering, allowing the entire Polish surgery community to bask in the brilliance of Professor Tang's honorary lectures. Social festivities, including a gala dinner for the entire Polish Federation of Hand Surgery, created memorable moments (Figure 10). Prof Tang also took time to visit the revered religious site of Jasna Góra, adding a touch of cultural significance. (Figure 11)



Fig. 10: Prof Tang visiting Jasna Góra Monastery



Fig. 11: Participants of the National Congress

The grand finale of the educational odyssey was in Szczecin (local host: Ireneusz Walaszek), an academic centre. This component of the tour started on 1st October 2023. Here the program deviated slightly, aligning with the commencement of the academic year. Social activities, including a guided tour around the old town, a visit to the museum of regime change, and a concert at the Szczecin Philharmonic, added a delightful touch. An unusual yet enriching opportunity involved a stroll in the manifestation of the academic community of Szczecin's universities. (Figure 12)



Fig. 12: Prof Tang joins the academic walk with university authorities

The scientific program in Szczecin was equally vibrant, with meetings with young scientists, enthralling lectures on ethics in scientific work, hands-on workshops on scientific paper writing with medical students, and spirited discussions on upper limb fracture cases and lectures on expert tendon reconstruction and rehabilitation. The visit concluded with a poignant farewell dinner, a summary of the enriching journey with the president of the Polish Hand Society and the hosts of the various centres. (Figures 13-15)



Fig 13: Anatomical model course



Fig. 14: Meeting with young scientists



Fig. 15: Prof Tang's farewell dinner with the Polish Society's President and the local hosts

To summarise, several teaching activities took place:

- Two cadaver courses were conducted with 40 attendees.
- Live surgeries, clinical discussions, and clinical evaluations occurred in four academic centres.
- The biannual meeting of the Polish Society for Surgery of the Hand took place, including an honorary lecture.
- The inauguration of the Academic Year at Pomeranian Medical University in Szczecin featured Professor Jin Bo Tang as the honorary guest.
- A workshop for young scientists with 40 attendees included ethical lectures.
- A meeting with young surgeons and two practical courses on tendon surgery were held.
- Numerous lectures were conducted in five hand surgery centres (Poznan, Warsaw, Lodz, Wroclaw, Szczecin).

As the visit drew to a close, it was time to bid adieu to Professor Tang. Undoubtedly, this unique period marked a turning point for Polish hand surgeons – an unparalleled opportunity to forge connections, amass knowledge, and foster enduring friendships. Personally, meeting the professor in the flesh and delving into his treatment philosophy has been profoundly enriching, undoubtedly elevating my surgical prowess. Here's to hoping for similar experiences and pathways of improvement for myself and all hand surgeons!

**IRENEUSZ WALASZEK MD PhD**  
IFSSH Delegate of Polish Society for Surgery of the Hand

## IFSSH HAROLD KLEINERT VISITING PROFESSORSHIP FOR YOUNG SCIENTISTS AND MEDICAL STUDENTS WORKSHOP

On 1-2 October 2023, Professor Jin Bo Tang visited Pomeranian Medical University in Szczecin, Poland, as a part of a two-week IFSSH Harold Kleinert Visiting Professorship.

The first day's workshop combined lectures on tendon healing biology and surgical strategy in current tendon repair practice, with practical training on artificial tendon models with the M-Tang suture technique. This was followed by a lecture on treatment of hand fractures with practical sessions on artificial bones with implants.

Karol Nicieja (4th year medical student): "Professor Tang's lecture on tendon healing was extraordinary. What struck my attention was the emphasis on basic science. It was so honest and inspiring to hear the personal story of a hand surgeon who was persistent in a deeper understanding of the fundamentals behind the healing of surgically treated tendons. I was overwhelmed by the open communication and such drive to share one's knowledge and passion. With more and more advances in clinical research, we tend to forget the significance of understanding the scientific basis behind them. I was surprised by how proper comprehension can help us as future clinicians develop better strategies and treatment plans for our patients".

Malgorzata Rybarczyk (medical intern): "It was so great to see the author of the technique performing the tendon suturing, being surrounded by people whose careers were still lying in the future".

A unique workshop on medical research ethics and ethics in publication was conducted on the second day:

### Workshop 1:

- Limitations of evidence-based practice (EBM) and

wrong information-based practice (15 min) by Professor Jin Bo Tang

- Discussion on EBM (30 min)
- How can we encourage good publication ethics? (10 min) by Professor Jin Bo Tang
- Discussion on authorship, study design, and misconducts (20 min)

### Workshop 2:

- Medical research: hypothesis, scientific questions, and end-points by Kaja Giżewska-Kacprzak (30 min)
- Discussion (10 min)
- Impact Factor vs H-Index by Kaja Giżewska-Kacprzak (10 min)

### Workshop 3:

- Systematic review vs meta-analysis by Kaja Giżewska-Kacprzak (30 min)

After each of above workshops, the lectures were followed by practices on examples and discussion of cases.

The workshops focused on proper authorship and authorship criteria for scientific publications, reporting results based on solid facts found during research, and improving medical research designs. The workshop stimulated hot discussions and emphasized the need of such workshops and education before participating in medical research. Such essential ethical knowledge is not sufficiently taught at medical schools, and many researches, even mentors, lack this knowledge.

Kaja Giżewska-Kacprzak organised these workshops. She commented: "As an academic teacher, researcher, and clinician, I can observe the overwhelming pressure of collecting impact factor points within medical society. Unfortunately, the measuring tool became a goal of its own. Having read papers by Professor Jin Bo Tang on this subject I was honoured to invite such an expert to our workshop about traps of Evidence-Based Medicine (EBM) and publication ethics.

We have gathered an audience of both medical

students and young residents, so it was ideal to implement a strategy to discuss the limitations of EBM, the importance of good quality studies, and ethics, with people at the beginning of their medical journey. Students were sharing tables of 4 and moderators were sitting between the participants. The concept of an interactive workshop including group exercises and open discussions was designed to create a friendly environment for sharing participants' personal views, including vivid discussions during one coffee break! As an academic teacher, I will be happy to offer this workshop format as a part of the curriculum of medical studies in the future".

Bartosz Gajek (5th year medical student): "I was moved by the story about honesty and responsibility in our work. Professor Tang shared with us examples from his years of individual research and as the former Editor in Chief of the Journal of Hand Surgery (European Volume) his extraordinary work in safeguarding sound ethical standards of publications. It allows us to note the wrong information-based practice when poor methodology is used or improper reports are made. The quality of studies is important in the reported evidence. We learned about the complicated path from critical judgment of research conclusions to clinical implications".

Karol Nicieja (4th year medical student): "It was a unique opportunity for me to discuss how to improve our student scientific society, with truthfulness and integrity. To have a mentor who exhibits exemplary ethical behavior is crucial in science. Following this mindset we can further share experiences with colleagues to make a change from the ground up.

I know I can object when faced with unethical research practices. I got an amazing boost of inspiration for my future work. At the same time, I feel encouraged to become an advocate of good practices despite being at the beginning of my education. The workshop was an opportunity to be heard and talk freely. I hope more hours of our education could have such a format."



**Fig. 1: Workshop about ethics and good practices in medical research (Kaja Giżewska-Kacprzak was standing to direct the practices of the workshop)**



**Fig. 2: A lecture given by Professor Jin Bo Tang in the workshop about ethics and good practices in medical research**



**Fig. 3: Professor Tang discussing with faculties and medical students.**



**Fig. 4: Professor Tang (left) in discussion with medical students at tea break (from the right: Magdalena Zawadzka, Karol Nicieja and Bartosz Gajek).**



**Fig. 5: Dr Kaja Giżewska-Kacprzak, hand surgeon and workshop organiser, holds copies from the hand literature for the attendees to practice study design and reporting study data on.**

#### AUTHORS:

#### **IKAROL NICIEJA,\* BARTOSZ GAJEK, MAŁGORZATA RYBARCZYK,**

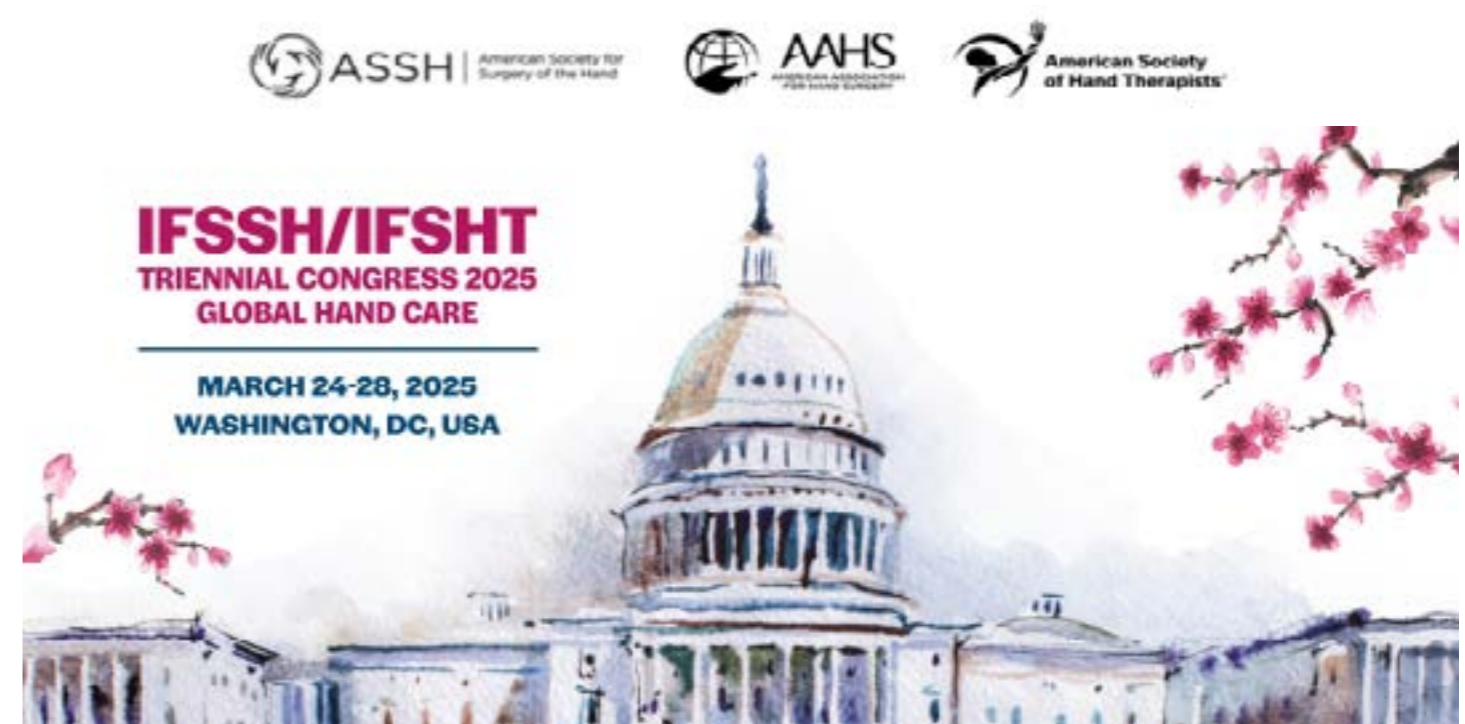Medical students, Pomeranian Medical University, Szczecin, Poland

#### **IRENEUSZ WALASZEK, KAJA GIŻEWSKA-KACPRZAK\*\***

Department of Paediatric and Oncological Surgery, Urology and Hand Surgery  
Department of Orthopedics, Traumatology and Orthopaedic Oncology  
Pomeranian Medical University, Szczecin, Poland

\*[karolnicieja@gmail.com](mailto:karolnicieja@gmail.com)

\*\* [kaja.gizewska.kacprzak@pum.edu.pl](mailto:kaja.gizewska.kacprzak@pum.edu.pl)



### IFSSH - AAHS/ASSH TRAVELING FELLOWSHIP

The IFSSH-IFSHT 2025 Triennial Congress hosts, the International Federation of Societies for Surgery of the Hand (IFSSH), the American Association for Hand Surgery (AAHS), and the American Society for Surgery of the Hand (ASSH) are offering traveling fellowship opportunities to eligible applicants to attend the [2025 Congress in Washington, DC, USA](#).

Up to twenty-four (24) \$5,000 travel fellowships will be awarded, which will include complimentary registration for the Congress and a multi-day visit with an ASSH/AAHS member host center to learn and for clinical/surgical observation.

#### ELIGIBILITY

- Applicants must be surgeons between 30 and 45 years of age.
- Applicants must have completed their surgical training and be early in their surgical career.
- Ideal applicants are teachers; individuals who are excited to learn and educate others.
- Applicants must have the ability to communicate in English.

Individuals who meet these eligibility requirements are encouraged to apply to receive a traveling fellowship for this valuable experience.

#### **APPLY FOR A TRAVELING FELLOWSHIP NOW**

Travel grants are available for therapists to attend the 2025 IFSSH-IFSHT Congress. Please encourage your therapy colleagues to [apply for this opportunity](#).



## ACTIVITIES OF THE LATIN AMERICAN FEDERATION OF HAND SURGERY 2024-2025



At the XIX Congress of the Latin American Federation of Hand Surgery (FLACM), which was held from 6-11 November 2023, Dr. Sergio Daroda was elected President, and Dr. Fernando Menvielle became the Secretary, representing the Argentine Association of Hand Surgery (AACM).

During the event, they described the objectives set for the next two years as follows:

- Enhancing the standing of FLACM by being present and supporting the development of Hand Surgery in countries that require assistance.
- Stimulating the participation of all hand surgeons from Latin America in academic activities.
- Creating continuity policies to assist and guide the incoming leadership in the decision-making process of the Executive Committee.

Furthermore, a detailed schedule of activities planned until the upcoming FLACM Congress in Buenos Aires in October 2025 are provided below:

- 1st Joint Meeting with the Uruguayan Society of Hand Surgery, Montevideo, Uruguay, 8-9 December 2023.
- Round Table at the IFSSH Mid-Term Course, Quito, Ecuador, 28 January–2 February 2024.
- 1st Paraguayan Congress of Hand Surgery, Asuncion, Paraguay, 5-6 April 2024.
- Online Round Table with the Colombian Association of Hand Surgery, May 2024.
- 1st Bolivian Congress of Hand Surgery, La Paz, Bolivia, 18-19 July 2024.
- FLACM Round Table, Brazilian Congress of Hand Surgery, Florianopolis, Brazil, August 2024.
- Online Round Table with the Brazilian Society of Hand Surgery, September 2024.
- 2nd Peruvian Congress of Hand Surgery, Lima, Peru, 17-18 October 2024.
- 1st Guatemalan Congress of Hand Surgery, Guatemala City, Guatemala, 21-22 November 2024.
- Joint Meeting with the Costa Rican Society of Hand Surgery, San Jose, Costa Rica, 2-4 May 2025.
- Online Round Table with the Chilean Society of Hand Surgery, May 2025.
- Joint Meeting with the Venezuelan Society of Hand Surgery, Caracas, Venezuela, 18-20 June 2025.
- Online Round Table with the Mexican Society of Hand Surgery, August 2025.
- 20th Congress of the Latin American Federation of Hand Surgery, Buenos Aires, Argentina, October 2025.

### The various committee members are herein presented Executive Committee:

Dr. Carlos Martínez (AACM President 2013)  
Dr. Carlos Lupotti (AACM President 2014)  
Dr. Gabriel Clembosky (AACM President 2015)  
Dr. Cecilio Argañaraz (AACM President 2018)  
Dr. Martín Caloia (AACM President 2019)  
Dr. Diego Garat (AACM President 2023)  
Dr. Agustín Donndorff (AACM Secretary 2014-2021)

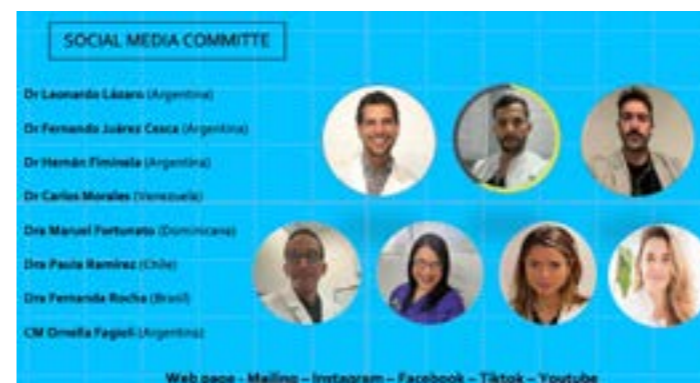

### Advisory Committee (FLACM Past Presidents):

Dr. Eduardo R Zancolli (1996-1997)  
Dr. Mario Rodríguez Sammartino (2010-2011)  
Dr. Rodolfo V Cosentino (2016-2017)  
Dr. Miguel Capomassi (AACM President - Congress FSCM 2007)

### Media and Communication Committee:

Dr. Leonardo Lázaro (Argentina)  
Dr. Fernando Juárez Cesca (Argentina)  
Dr. Hernán Fiminela (Argentina)  
Dr. Carlos Morales (Venezuela)  
Dr. Maruel Fortunato (Dominican Republic)  
Dr. Paula Ramírez (Chile)  
Dr. Fernanda Rocha (Brazil)  
Dr. Alberto Rojas (Colombia)  
CM Ornella Fagioli (Argentina)



### International delegate for the IFSSH:

Dr. Eduardo Rafael Zancolli (next 2 years)

A new communication design will be implemented, including the development of a website and the use of social media platforms such as Instagram

(flacm.official), Facebook (Flacm Flacm), TikTok (FLACM), and YouTube.

A fresh visual identity will be created, representing the activities of FLACM, using a colour scheme that represents each member country.

During the FLACM General Assembly, Colombia was elected as the country to lead the Federation for the 2026-2027 term, represented by Dr. Fabio Suárez.

### DRA AIDA GARCIA G

Ortopedista & Traumatologa UMNG  
Cirujana de mano y miembro superior HMC

## INDIAN SOCIETY FOR SURGERY OF THE HAND

### Report on the Golden Jubilee Celebration of the Indian Society for Surgery of the Hand, 2023

The Golden Jubilee celebration of the Indian Society for Surgery of the Hand was held on 8 September 2023 at the annual ISSH Conference, in short ISSHCON 2023, at Chandigarh in a glittering function befitting the rich history of the ISSH which was formed in 1973.

A specially designed Golden jubilee logo was unveiled, followed by video presentations on the history of the

ISSH, the history of the ISSHCONs over the years, and the list of orators who had enriched the ISSHCONs.

A video showing all the Past Presidents of ISSH and their contributions was shown. Homage was paid to the departed souls. The 12 Past Presidents who were in attendance were duly honoured on the dais with the Golden Jubilee Medallion.

A collective photograph of all these doyens was taken with the entire audience hopping on to the stage, not wanting to miss this golden opportunity! It was an emotional moment for all the members and the Past Presidents of ISSH.



## ISRAELI SOCIETY FOR SURGERY OF THE HAND



[www.issh.org.il](http://www.issh.org.il)

In the early 60's, a few members of the Israeli Orthopedic Society and the Israeli Plastic Surgery Society developed a special interest in surgery of the hand. Professor Isidor Kessler was the first to convert his occupation from general orthopedics to surgery of the hand as his primary and then sole profession. In order to do so, he first studied under the Boyes group in California, where he was active mainly in development of the Niebauer Prostheses. After his return to Israel, he opened the first service for surgery of the hand at the Kaplan Medical Center in the city of Rehovot.

In 1967, after the Six-day War, many upper limb injuries needed efficient and professional care. There were other wars to come, the War of Attrition and Yom Kippur War, with over 10,000 injured, about a third of which suffered from upper limb injuries. To deal with the injured, the Ministry of Health founded five medical units dedicated to surgery of the hand. Today there are hand surgery units in all medical centers in Israel as well as a hand surgery department at the Sheba Medical Center in Ramat Gan.

In 1975, Israeli surgery of the hand became known internationally following the first international symposium held in Israel with the participation of the American Association for Surgery of the Hand and other societies, alongside the Israeli surgeons.

In 1979 another international symposium was held in Tel Aviv.

In 1989, the Israeli Society for Surgery of the Hand (ISSH) was founded and hosted the fourth meeting of the International Federation of Societies for Surgery of the Hand (IFSSH) in Tel Aviv. Later on, more meetings were organized in cooperation with the Greek, Italian and French Societies. In 2000 the Israeli Society celebrated its tenth anniversary in an international convention in Jerusalem, with the participation of societies from around the world. In 2019, a celebration for the 30th anniversary was held at the annual ISSH meeting.



Since 1990, the Israeli Medical Association acknowledged surgery of the hand as an official fellowship. In order to be acknowledged as consultant for surgery of the hand in Israel, a fellow must undergo an orthopedic or plastic surgery residency, followed by a fellowship in surgery of the hand. The fellowship is two and half years, during which the candidate must participate in a specified list of surgical procedures as well as participate in symposiums, journal clubs and academic activities. The fellow must also pass written and oral board exams in hand and microvascular surgery. According to guidelines of the scientific board of the Israeli Health Organization, there must be at least two attending surgeons working full-time in order for the center to initiate a fellowship program.

The largest initiative to advance hand surgery in Israel was taken, without a doubt, by the late Professor Kessler, an IFSSH Pioneer in Hand Surgery. His work on subjects such as lengthening of fingers, repair of flexor tendons, among others, are international milestones.

The largest department for surgery of the hand was founded by Professor Joel Engel in the Sheba Medical Center, a large public medical center in Israel. Professor Engel finished his residency at Sheba and later his hand surgery fellowship with Professor Tubiana in Paris, Professors Nalebuff and Tupper in the United States and Vanio in Finland. Both Joel Engel and the following head of this department and a founder of microsurgery in Israel, Dr. Batya Yaffe, were designated Pioneers in Hand Surgery by the IFSSH.

The late Professor Weinberg founded the unit for surgery of the hand at the Hadassah Medical Center in Jerusalem. Professor Weinberg and his associate Professor Neuman, the chief of plastic surgery, were among the founders of surgery of the hand in Israel.

Professor Reiss founded the unit for surgery of the hand in Ziv Medical Center in Safed, and continued to work at the Rambam Medical Center in Haifa. Professor Reiss is one of the developers of the Kullen Nicole Reiss prosthesis for metacarpophalangeal joint arthroplasty. This prosthesis has had great success in the treatment of patients suffering from arthritis in Great Britain.

Dr. Karev continued as head of the department for surgery of the hand at the Kaplan Medical Center, after Prof. Kessler. Dr. Karev graduated fellowship training in the United States under Professor Kleinert.

These founders of hand surgery in Israel, since the 70's, taught and guided a generation of students who would grow to become the leaders of hand surgery in Israel and would serve the public with innovative treatment of all diseases and injuries of the upper limb.

There is a network of units and specialists in the field of hand surgery throughout Israel. The Israeli Society continues to organize two annual meetings, hosting numerous foreign guests each year. It also grants two annual grants - for best achievement in the fellowship board test and for best study presented by a young surgeon at an international meeting. There are approximately 50 active members in ISSH.

In 2012, the Israeli Group for Hand Therapist was formed under the ISSH and recognized by the International Federation for Societies of Hand Therapy. The therapists are today an integral part of hand surgery in Israel.



The Israeli Society is a member of the International Federation of Societies for Surgery of the Hand (IFSSH). In May 2023, the ISSH was accepted as a full member of the Federation of European Societies for Surgery of the Hand (FESSH) at the FESSH annual meeting in Rimini, Italy.

In 2017, a joint meeting with the German Hand Society was held in Jerusalem, including the participation of the Secretary General of FESSH.

In 2019, the Israel Society was guest society at the annual meeting of the Brazilian Society for Hand



Surgery, held in Gramado, Brazil.

In May 2023, a joint meeting was held with the American Society for Surgery of the Hand (ASSH) in Tel Aviv. ISSH continues to nurture international cooperation, advancing the care of hand surgery patients and the education of young surgeons, promoting research initiatives as well as public awareness of our profession in Israel.



Surgery of the hand is no longer a profession in the making but a well-recognized specialty with a great future.

#### **JOEL ENGEL, SHAI LURIA**

Past Presidents of the Israeli Society for Surgery of the Hand

## **VENEZUELAN SOCIETY OF HAND AND RECONSTRUCTIVE SURGERY OF THE UPPER LIMB (SVCMRMS)**

On the 11th of January 2024 the Venezuelan Society of Hand and Reconstructive Surgery of the Upper Limb (SVCMRMS) celebrated its Golden Anniversary!

One of the remarkable features of this achievement is that our Society has not only lasted, but has also grown during these 5 decades made up of members from many different backgrounds and customs. We remember fondly that Friday on 11 January 1974 when our Society was founded under the inspiration and tutelage of Dr Ricardo Sánchez Beaujon at the Dr Miguel Pérez Carreño Hospital by 9 Orthopaedic and Hand Surgeons, in the "classroom – the Little School" of the Hand Surgery Service (which today is dedicated to Dr. Alex Quintero, honouring his dedication and commitment to teaching).

Of the 9 Founding Members, only two are left, Dr. Antonio De Santolo R, and myself. May the departed colleagues find eternal rest. We remain firm in the idea of progress and growth of our Society.



**Some of the founding members: Dr Sánchez - Beaujon, Dr Contreras - Gamboa, Dr Capriles - illas**



The entrance of the service where the Society was founded

In 1975 a 3 year long Postgraduate University Course endorsed by the Central University of Venezuela (UCV), was established in Hand and Reconstructive Surgery of the Upper Limb, with new intakes every year, in total so far 48 classes. Subsequently, students from the first few classes have established more similar courses based on the inspiration by Dr. Sánchez Beaujon, for example in Caracas at the University Hospital (UCV), in Maracaibo by the University of Zulia (LUZ), in Barcelona and another in Puerto Ordaz endorsed by the University of Oriente (UDO). This resulted in new Hand Specialists every year, which added to the growth of our Society.

At the Children's Orthopaedic Hospital (FHOI) of Caracas, we have a Hand Surgery Unit, directed by me and staffed by some graduates from the aforementioned postgraduate courses. We have a special interest in paediatric hand surgery, and the study and treatment of congenital pathologies of the hand and upper limb. We run a 2 year advanced course in Congenital Hand Pathologies.

We are proud and happy as we celebrate the 50 years of the founding and growth of SVCMRMS.

Our hope is that this new year of 2024 which we begin, will be one of progress and opportunities for all of us.



The first issue of the Society's scientific magazine and Photo of the page with the first office bearers.



Dr. Rodolfo Contreras-Gamboa with some graduate students

Kind regards,



**DR. RODOLFO CONTRERAS-GAMBOA**  
 Founding Member and Past President of the Venezuelan Society of Hand Surgery (SVCDM)  
 Past President of the South American Society of Hand Surgery (1993)  
 IFSSH Pioneer 2016  
 rcontreras21n@gmail.com

**Junta directiva de la SVCM**  
 Esta directiva fue electa en el momento de la fundación, según los estatutos, subsecuentemente en las asambleas y concurrió en marzo de 1976, al traslado de la sede a la 1776 de Caracas, trasladándose en octubre de 1978.

1974-1976	Dr. Ricardo Sánchez Beaujon	Presidente
1976-1978	Dr. Rodolfo Contreras G.	Secretario
	Dr. Antonio De Sandoz B.	Tesorero
	Dr. José García M.	Subsecretario
	Dr. Luis Capriles I.	Vocal
1978-1980	Dr. Rodolfo Contreras G.	Presidente
	Dr. Antonio De Sandoz B.	Secretario
	Dr. José García M.	Tesorero
	Dr. Luis Capriles I.	Subsecretario
	Dr. Ricardo Sánchez B.	Vocal
1980-1982	Dr. Antonio De Sandoz B.	Presidente
	Dr. Argenteo Brice	Secretario
	Dr. Paul Mandujillo	Tesorero
	Dr. José Rafael Casanova	Subsecretario
	Dr. Rodolfo Contreras G.	Vocal
1982-1984	Dr. Rodolfo Contreras G.	Presidente
	Dr. Argenteo Brice	Secretario
	Dr. Flaky Nájera	Tesorero
	Dr. José Rafael Casanova	Subsecretario
	Dr. Antonio De Sandoz	Vocal
1984-1986	Dr. José Rafael Casanova	Presidente
	Dr. Flaky Nájera	Secretario
	Dr. José D. Barrios	Tesorero
	Dr. Rafael Briceño	Subsecretario

## POLISH SOCIETY FOR SURGERY OF THE HAND

### A Snapshot of Hand Surgery in Poland: Reflecting on 2023

In 2023, the field of hand surgery in Poland saw a mix of challenges and progress. Amidst Russia's invasion of Ukraine and an important election year for the Polish Society for Surgery of the Hand, the year was marked by both significant events and impactful initiatives.

#### Supporting Ukraine:

Continuing our commitment from 2022, we extended support to Ukrainian hospitals by donating vital surgical equipment. This on-going effort aimed to alleviate the pressing medical requirements resulting from the conflict, emphasises our solidarity with the Ukrainian people.

#### Here are the highlights of 2023:

AO Trauma Course—Management of Fractures of the Hand and Wrist with anatomical specimen (27-28 January 2023). The course was organized by the AO Foundation and supported by a national faculty of experts in hand surgery. As usual it contained several evidence-based lectures, laboratory practicals, where surgeons got hands-on learning of basic principles and practical know-how needed for live surgery. In the practical exercises with anatomical specimens, participants were trained the application of soft tissue management and fixation techniques. Discussing cases in small groups helped participants to understand decision-making and management skills.

The Congress of the Polish Society for Surgery of the Hand was held in Czestochowa from 28 to 30 September. It proved to be a high-energy gathering. This congress brought together our surgical community and featured international speakers Professor Jin Bo Tang, Dr. Lorenzo Garagnani, and Dr. Adil Trabelsi. Alongside the informative sessions, we also elected new management board members during

the general assembly. The management board is elected for a 2-year term.

Social festivities, including a gala dinner for the entire Polish Society of Hand Surgery, created memorable moments.



Profesor Tang with participants of the young scientist's workshops. Szczecin 2023



Participants and faculty of the cadaver course Poznań 2023

One of the most important events was the visit by Professor Jin Bo Tang (thanks to the 2023 IFSSH Harold Kleinert Visiting Professor Sponsorship) from 17 September to 2 October 2023. His tour across six academic centres was a remarkable learning opportunity. He is renowned for his expertise of tendon surgery and hand trauma treatment, and shared invaluable insights, leaving a lasting impact on our hand surgery community.

The webinar series delivered by local and international speakers proved to be popular and becomes a 'regular favourite' on the PSSH educational calendar. Particularly noteworthy was the session on Spastic Hand Diagnosis and Treatment, led by international faculty member Dr Caroline Leclercq from France.

We are moving forward into 2024 with excitement and forge on, prepared to tackle what lies ahead. Our dedication remains unwavering in advancing hand surgery and standing in solidarity with those in need, both within our community and particularly in Ukraine.

#### **IRENEUSZ ADAM WALASZEK**

MD PhD Hand Diploma FESSH

IFSSH Delegate of the Polish Society for Surgery of the Hand

## **PORTUGUESE SOCIETY FOR SURGERY OF THE HAND (SPOCMA)**

The Portuguese Society for Surgery of the Hand (SPOCMA) had a rich and intense 2023, full of scientific and educational activities. From the agenda we can highlight the following:

- We organized the 1st Wrist and Hand Arthroscopy Course on Cadavers, held with great success in September in Porto, in the presence and guidance of national pioneers of wrist arthroscopy.



- We expanded our National Hand Surgery Fellowship Program which runs in Lisbon, Porto and Coimbra. This project promotes hand surgery education in Portugal, amongst residents and young specialists in Orthopaedic and Plastic Surgery. They can spend time with leading hand surgeons, improving their experience and knowledge.

- Every 3 years, we celebrate an Iberian Joint Congress along with the Spanish Hand Surgery Society (SECMA). Last year, it was held in Granada, Spain (19-21 April), during an amazing 3-day scientific program, along with several pre-congress courses and much personal networking.

- In May, we travelled to Rimini, Italy, to enjoy the FESSH spirit with all the European hand surgery Societies, and shared the Portuguese hand surgery expertise during another fantastic FESSH Annual Meeting.

- We organized two one-day seminars with specific themes in hand surgery: Trapeziometacarpal Arthritis (April) and Arthroplasties (November)

- SPOCMA also provided scientific support for many other national events.

- A big project launched in 2023, will be our next National Congress to be held with the ILA (Ibero-Latin-American) Group Congress, and with the German



Society of Hand Surgery as the guest society. It will take place in Coimbra, 3-5 October 2024 and will also have the institutional presence of the Spanish Society of Hand Surgery.

Therefore, we extend a sincere invitation, to all hand friends, to come to Coimbra in 2024. We hope you will also experience unforgettable moments in a historic Unesco City.

Best wishes for 2024, hope to see you soon, as well as in Coimbra!



**JOSÉ ALEXANDRE MARQUES**

[josealexmarques@hotmail.com](mailto:josealexmarques@hotmail.com)

## **NORWEGIAN SOCIETY FOR SURGERY OF THE HAND**

### **MODERN TREATMENT OF FROST BITE**

The Norwegian Society for Surgery of the Hand's annual national meeting took place on 26-27 October 2023 in Oslo. The event, held jointly with the Orthopaedic Society, also welcomed plastic surgeons specializing in hand surgery. In Norway, hand surgery is not a distinct specialty but is performed by both orthopedic and plastic surgeons. The meeting featured research presentations, case studies, symposia, and our general assembly.

Each year, we host a two-hour symposium covering various topics that attracts both hand surgeons and general orthopedic or plastic surgeons. This year's symposium, organized by the University Hospital of North Norway in Tromsø, featured four plastic surgeons as lecturers—a first in the symposium's history. The theme explored different soft tissue coverage techniques for the hand and arm, ranging from skin grafts to free flaps. Anne Maret Dønland (Tromsø) discussed skin graft types, indications, procedures, and potential pitfalls. Katrin Valen Ek (Tromsø) showcased reliable local flaps, while Cecilie Lind (Bergen) delivered an impressive lecture on advanced regional and free flaps. These presentations served as a practical guide for addressing simple soft tissue problems independently and seeking assistance in more complex situations. The audience responded positively, finding the information valuable for both experienced and less-experienced surgeons.

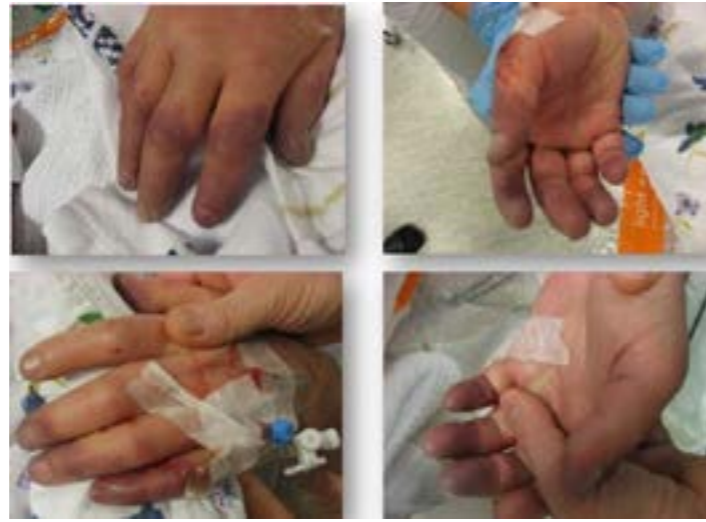The first topic for this year's symposium was frostbite, presented by Katrin Valen Ek (Tromsø), and we would like to focus on this here, considering the significant advancements in this field over the last decade(s), leading to what many describe as a paradigm shift. Professor Louis de Weerd, unable to attend physically, presented alongside radiologist and PhD Sven Weum, both from Tromsø, through a video presentation.

They are part of the Dermatoplastic Imaging Research Group at UiT the Arctic University of Norway, researching skin perfusion.

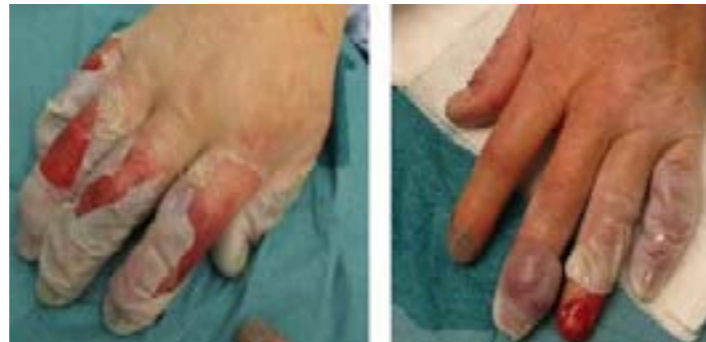De Weerd has dedicated over ten years to frostbite treatment. The University Hospital of North Norway in Tromsø has extensive experience in frostbite injuries due to the cold climate, long winters, and military exercises like "Cold Response" for NATO. In the past, frostbite treatment involved a passive "wait and see" approach, often leading to amputation months later. However, the last two decades have witnessed a shift from passive to active treatment, "from knife to needle," resulting in a significant decrease in rates and level of amputation.

Active treatments, including thrombolysis or vasodilatation with iloprost, aim to enhance blood supply and reduce ischemic necrosis. Frostbite is gently rewarmed in warm water, graded according to Cauchy, and assessed for amputation risk. Iloprost is administered intermittently via intravenous transfusion over 3-5 days, starting within 72 hours of rewarming. Thrombolysis, with potential serious adverse effects, should only be part of a research protocol. Severe cases may receive hyperbaric oxygen treatment to further reduce amputation risks and level of amputation. To increase vasodilatation and address pain, an axillary brachial plexus block with local anesthesia, preferably by catheter for a few days, and/or botulinum toxin (Botox) around the main arteries at wrist level or finger base are viable options. Botox can also alleviate long-term cold intolerance.

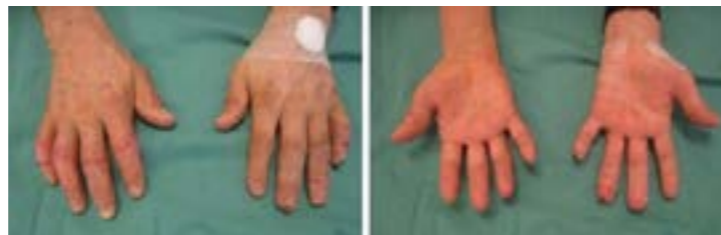The audience was urged to treat frostbite as an emergency, applying active treatment to severe cases (Cauchy grade 2-4) following published algorithms. The most severe cases should be discussed and, if necessary, transferred to specialized units like The University Hospital of North Norway, where active treatments have dramatically reduced amputation rates and level.



**Figure 1: 72yr old male, alcohol++, outdoor in -31 . Cauchy grade 3, with high risk of amputation.**



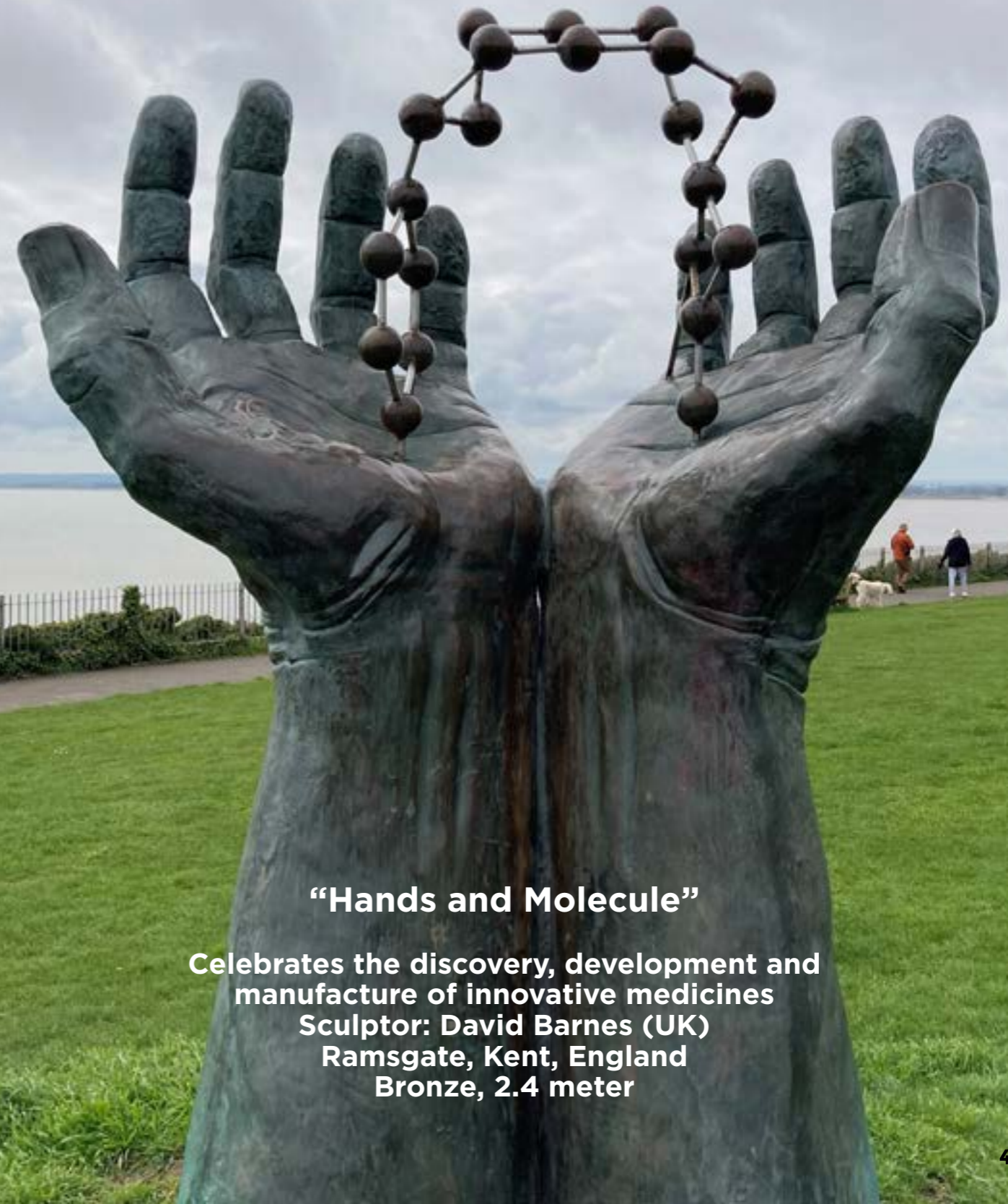
**Figure 2: Iloprost infusion was given; big bullae formation was seen.**



**Figure 3: After 4 weeks. Only a very distal necrosis on his left 5th finger.**

**KATRIN VALEN EK** (President)  
Rasmus Thorkildsen (IFSSH Delegate)  
On behalf of the Norwegian Society of Surgery for the Hand

## Art Exhibit #19



### “Hands and Molecule”

**Celebrates the discovery, development and manufacture of innovative medicines**  
**Sculptor: David Barnes (UK)**  
**Ramsgate, Kent, England**  
**Bronze, 2.4 meter**

# Exercise Prescription App “Hand Therapy”

## Introduction

Carpal tunnel decompression remains the most common hand operation carried out in the UK, with 53,000 procedures carried out in secondary care each year. With the increasing prevalence of predisposing factors such as diabetes and obesity and with an aging population, the demand for elective hand surgery is predicted to significantly increase. With increasing demand, strategies are needed to reduce treatment costs while maintaining care standards (Palial 2019).

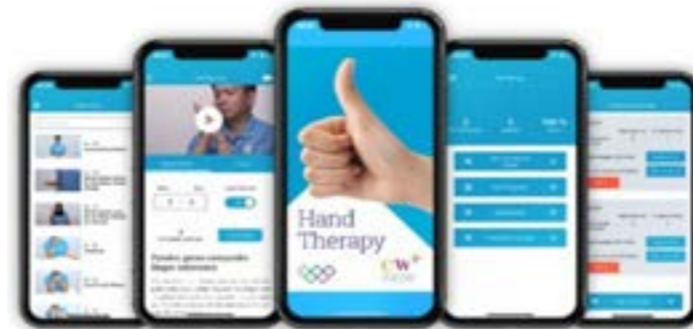The Getting It Right First Time (GIRFT) programme aims to improve patient outcomes and reduce unwarranted variations in services through data-driven improvements (BSSH, 2022). For hand therapy, a key focus is implementing standardised care pathways for common conditions like carpal tunnel syndrome.

The opportunity arose to address this demand by utilising the Hand Therapy app (HTA) (CW+, 2022) to develop a GIRFT recommended pathway of care for patients undergoing carpal tunnel release surgery.

Using a hand therapy mobile app can support delivering consistent, high-quality care aligned with GIRFT goals.

The award-winning HTA app enables therapists to prescribe personalised home exercise programmes to patients' phones, with videos, education, and reminders to support adherence and self-

management (Fig 1). Valdes et al (2021) recommend the HTA as a tool to prescribe home exercise programmes.



**Figure 1: Chelsea and Westminster Hand Therapy App**

## Background

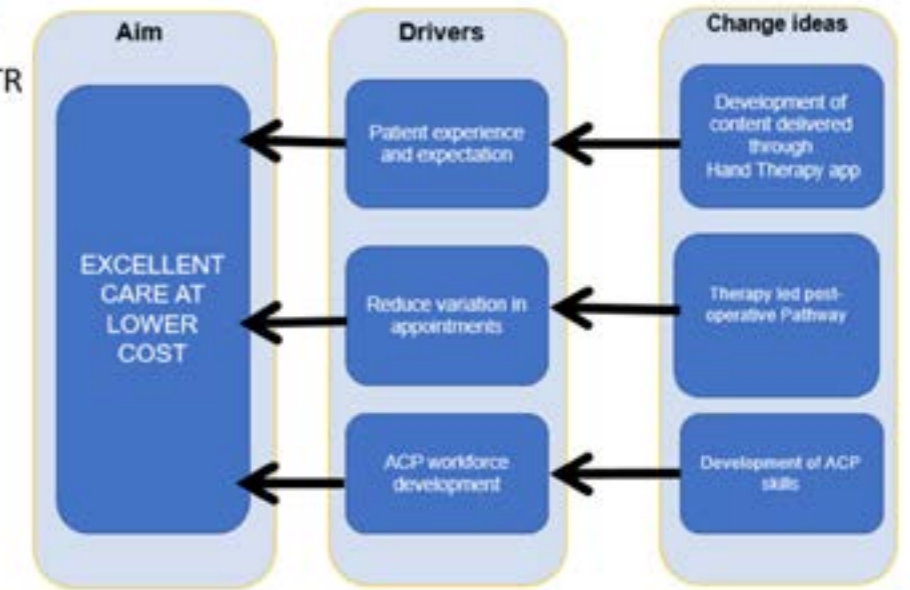
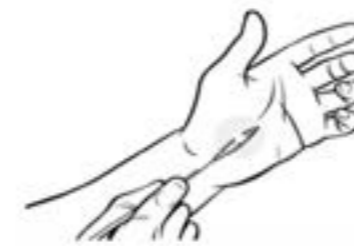At the Chelsea and Westminster Hospital Hand unit, approximately 200 carpal tunnel release procedures are performed annually. Initial data collection in 2021 uncovered several points of variation in the pathway:

- Inconsistent pre/post-op information provided to patients
- Varying number and location of post-surgical follow-ups (consultants, specialist plastics or GP nurse practitioner)
- Patients presenting later with avoidable problems due to lack of early intervention
- Patient engagement giving “voice to the customer” highlighted insufficient post-discharge recovery information and lack of a reliable point of contact as key issues



Recommends following CTR

- Two appointments
- At 14/7 and 6/52 weeks
- Led by an ACP therapist
- 6/52 virtual appt
- Option of PIFU



**Figure 2: Development of a Therapy Led pathway for post-op carpal tunnel syndrome based on GIRFT recommendations by BSSH**

Quality Improvement methods were used to develop the therapy-led CT pathway (TLCTP) aiming to provide excellent care at lower cost by freeing surgeons to other work. Utilising the skills of Hand therapists develops the AHP workforce but provides the “right treatment, by the right person at the right time”. Streamlining appointments improves experience and virtual appointments reduce travel to appointments, supporting National Health Service (NHS) sustainability. As the NHS aims for new healthcare delivery models, innovative technology (such as the HTA integrated into the TLCTP pathway is an enabler to self-management) is an important factor in patient adherence (O’Brien 2012; NHS England, 2023) (Fig 2.).

## Our improvement aims:

- 100% of patients\* undergoing a CTR to be seen on new pathway
- Monitor complications (aiming <9% the local pre-pilot complication rate)  
\* met the inclusion criteria

## Outcome measures:

- ≥60% virtual 6-week follow-up (using DrDr appointment platform links to the electronic patient record (EPR) system\*)
- ≥70% of patients to utilise the HTA to support self-management\*
- BCTQ outcome measure  
The BCTQ questionnaire was developed into an e-form using ISLA, a digital platform which links to EPR. The questionnaire automatically triggers prior to the 6-week review appointment, sending it to patients to complete and auto-populating their record with response data.

\*% based of pre-pilot patient engagement and HTA usage

## Balancing measures:

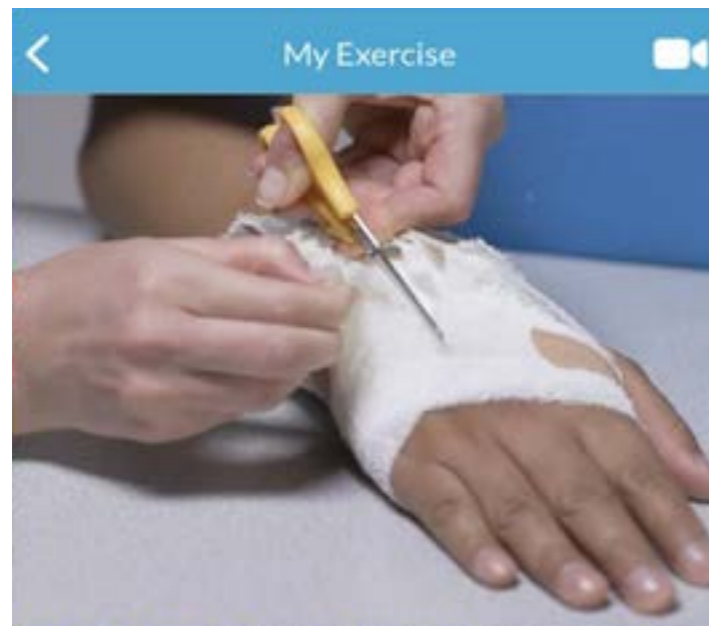
- Patient experience would be compared to pre-pilot data
- Decrease follow-up ratio

**Pathway Process**

The HTA provides standardised information and exercises for self-management in the first weeks after surgery; dressing changes, wound care and exercises.



**Figure 3: An example of an exercise video that can be accessed via the Hand Therapy App. The App content includes exercises, scar management, desensitisation advice**



**Figure 4: The digital bundle also includes: How/when to remove the outer post-op bandaging, Wound management, Finger tendon gliding exercises, Elevation/oedema management, Advice on function and timeframes for recovery, Animated educational content specific to CTR\*. (\*animation currently in production)**

Patients are advised to download the app via the discharge packs, and what content to add populating to MY EXERCISES. Further content can be added as patient's progress. Content can be personalised by adding clinician notes. Timed reminders can be set to encourage adherence to home programmes.

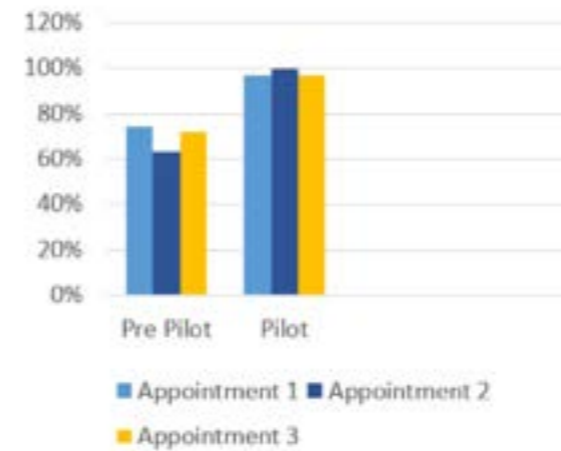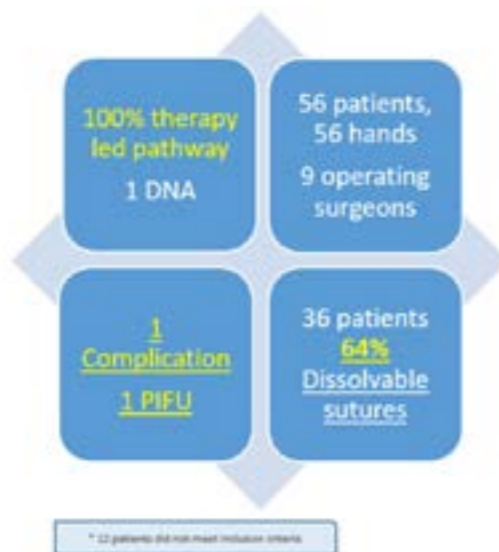
Patients were provided with a single point of contact to escalate concerns with the option of patient-initiated follow-up (PIFU) prior to planned appointments given.

A pilot was undertaken to test and evaluate the pathway. We used a tool Failure Mode and Effect Analysis (FMEA) to identify all potential risks in the pathway processes, for areas of high consequences. For example, in the case of suspected infection we mitigated for this and ensured robust escalation processes were in place.

For the pilot a three-appointment pathway was implemented to ensure clinical safety/effectiveness and provide reassurances to stakeholders. Patients were seen at 4-7 days (wound review), 10-14 days (suture removal) and 6 weeks post-surgery (surgical review).

**Results**

Results from the pilot are provided in Fig 5.



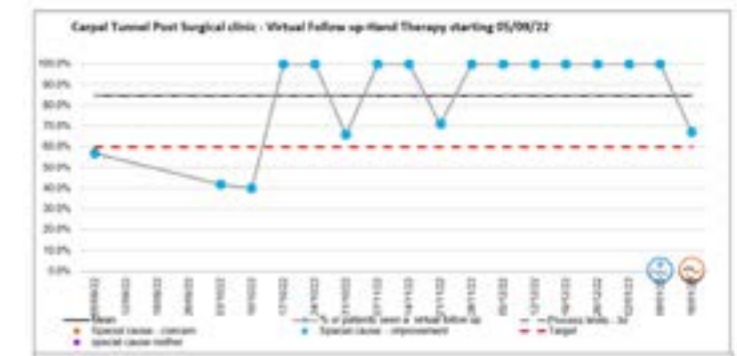
**Figure 5: 56 patients/100% of suitable patients were seen over a three-month period. There was one complication (<2%) of a stitch abscess. Overall, there was an improvement in the timeliness of follow-up appointments across all three post-op appointments. 97% saw a HT at 3-7 days post operatively compared with 74% pre-pilot, 100% compared with 63% at 10-14 days and 97% compared with 72% at 6 weeks post operatively**

Our pre-pilot data found that at the initial appointment 50-60% were seen by a specialist plastic surgery nurse, and of these 37% were additionally seen by a surgeon. The remaining 30-40% were seen by GP practice nurses. On the new pathway all patients were seen in one location by a therapist who could provide all their post-operative care needs, wound management, exercises, scar management and ADL advice.

Overall patient experience improved (Table 1) from 50% to 80% patients reporting Excellent/Good experience in favour of the therapy led pathway. Figure 6 provides data on virtual follow up appointments.

**Table 1: Patient experience data**

Pre-pilot
50% Good/Excellent quality of care
60% felt they were followed up at the right time
60% would be happy to see an experienced therapist instead of their surgeon
60% would be happy to be seen for a virtual follow-up
Post Pilot
81% Good/Excellent quality of care
82% felt they were followed up at the right time
81% happy to see an experienced therapist instead of their surgeon
60% happy to be seen for a virtual follow-up



**Figure 6: The percentage of patients with virtual follow-up, apart from the initial drop below our target as the pathway was established, we have been successfully reaching and exceeding our target of for virtual follow-up.**

**Uptake of the HTA**

To support the early patient self-management after surgery our target was >70% of patients downloading the HT app. From our data 91% of the cohort had smartphones, however there was marked variation in the uptake of the app prior to their first appointment with on average only 20% downloading the HTA. This improved significantly to >70% uptake when they were signposted to the HTA by a clinician and its purpose was explained.



**BCTQ**

40% completed before the virtual appointment and 90% completed when prompted at appointment. The Boston Carpal Tunnel Questionnaire is a validated outcome measure for assessing carpal tunnel syndrome symptoms and function (Multanen 2020). Though agreed locally to collect this data, we found scores at 6 weeks after surgery does not reflect the optimal time period for recovery. Also, inconsistent pre-surgery data collection prevented comparison.

**Discussion:**

The pilot demonstrated the pathway was safe and effective, and the next step was the two-appointment pathway. However, this relied on patients downloading and accessing HTA content prior to their first appointment.

The uptake of the HTA was >70% when the therapist signposted them to it. The next iteration of the pathway relied on patients downloading it on the day of surgery. The most common reason patients cited for not downloading the app was they had not looked in their discharge pack.

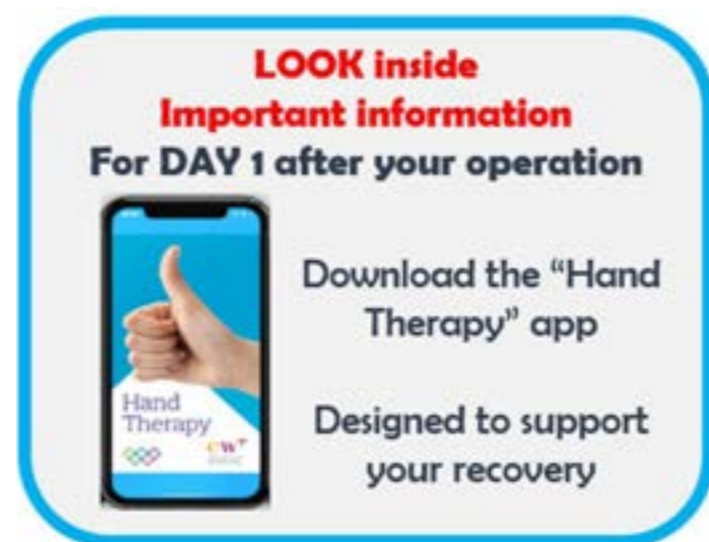To address this, we created customised packs with stickers prompting patients to examine the contents and specifically to "download the app". We also included dressings and sleeves to equip patients to change their dressings after watching the video. By guiding patients to the app resources and supplying dressings, we enabled an efficient two-appointment pathway where patients actively participated in their recovery.

Using the model for improvement plan, do, study, act (PDSA) further data was collected. An additional 139 patients have been seen on the two-appointment pathway. There were two (1.4%) complications and two PIFU. We maintained 70% virtual FU at 6 weeks. This simple idea of stickers on the discharge pack made a big impact, with 80% uptake of the HTA download ahead of the first appointment

(improvement of 60%). Of those using the HTA app 71% of patients were able to remove their own bandaging and change their dressing ahead of their first appointment for removal of sutures. For those not able to remove the bandaging themselves there was no negative impact as this could be done in the appointment without detriment to recovery.

**Summary:**

The therapy led post-surgical carpal tunnel pathway utilising HTA is safe, effective, and efficient. Digital integration can enhance pathway process and design and empower patient self-management. The HTA enhanced the TLCTP pathway by enabling patient participation, but only when accessed at the optimal time. Focusing on this timing was key to successfully implementing the GIRFT pathway. The TLCTP utilising the HTA is replicable as the app is free to download worldwide on IOS and Android (Fig. 7)



**Figure 7: The Hand Therapy app is free to download worldwide on IOS and Android**

**What's next?**

The carpal tunnel pre- and post-surgery animation is being completed to further supplement the TLCTP to be added to the app early 2024. This has been created with patients to ensure we are including what is important to them. The educational content is currently audio only. This would ideally have been created prior to the pathway implementation but has been delayed as this has been developed alongside clinical commitments.

Patients have said they would like the HTA information at the time of consenting and/or being given their surgery date to help to prepare. Therapists have a valuable part to play in preparing patients for surgery, managing expectations, anxieties, and the practicalities of how to manage activities of daily living (ADL) while they recover.

Evidence suggests this has potential to have a positive impact on post-operative pain response Feninets (2022) and Lee (2018). The HTA has the potential to be utilised as part of this process by supporting information and health literacy in the lead up to surgery.

**Acknowledgements:**

Raelene Marx Advanced Clinical Practitioner (MSK Upper Limb) Chelsea and Westminster Hospital - For pioneering the therapy led carpal tunnel pathway  
Victoria Rainey Improvement Advisor and Physiotherapist Barts Health - Whipps Cross University Hospital for QI project support  
CW+ official charity of Chelsea and Westminster Hospital NHS Foundation Trust for funding the HTA  
Imagineear – HTA developer  
CW+ Innovation Digital Health London – Horizon Digital Fellowship 2022/2023

**References**

- British Society for Surgery of the Hand. Getting It Right First Time (GIRFT). 2022. [https://www.bssh.ac.uk/\\_userfiles/pages/files/professionals/girft/girft-carpal\\_tunnel.pdf](https://www.bssh.ac.uk/_userfiles/pages/files/professionals/girft/girft-carpal_tunnel.pdf) (accessed December 4, 2023)
- CW+. New Hand Therapy app from Chelsea and Westminster Hospital NHS Foundation Trust improves patient experience. 2022. <https://www.cwplus.org.uk/news/2022/12/06/new-hand-therapy-app-from-chelsea-and-westminster-hospital-nhs-foundation-trust-improves-patient-experience> (accessed December 4, 2023)
- Feninets V, Adamakidou T, Mantzorou M, Mastrogiannis D, Govina O, Tsiou C. The Effect of Preoperative Educational Intervention on Anxiety and Pain of Patients Undergoing Spinal Decompression Surgery: A Pilot Randomized Controlled Study. *Cureus*. 2022 Aug 25;14(8):e28368. doi: 10.7759/cureus.28368. PMID: 36171848; PMCID: PMC9508614.
- Lee CH, Liu JT, Lin SC, Hsu TY, Lin CY, Lin LY. Effects of Educational Intervention on State Anxiety and Pain in People Undergoing Spinal Surgery: A Randomized Controlled Trial. *Pain Manag Nurs*. 2018 Apr; 19(2):163-171. doi: 10.1016/j.pmn.2017.08.004. Epub 2017 Nov 15. PMID: 29153299.
- Multanen J, Ylinen J, Karjalainen T, Ikonen J, Häkkinen A, Repo JP. Structural validity of the Boston Carpal Tunnel Questionnaire and its short version, the 6-Item CTS symptoms scale: a Rasch analysis one year after surgery. *BMC Musculoskeletal Disord*. 2020 Sep 12; 21(1):609. doi: 10.1186/s12891-020-03626-2. PMID: 32919457; PMCID: PMC7488577.
- NHS England. Supported self-management. 2023. <https://www.england.nhs.uk/personalisedcare/supported-self-management> (accessed December 4, 2023)

O'Brien The evidence of the way to improve patient's adherence in Hand Therapy. Journal of Hand Therapy Guest editorial Vol 25, issue 3 2012 doi: org/10.10/j.jht.2012.03.006

Palial V, Kheiran A, Siddiqui S. Carpal tunnel decompression in primary care: what is the infection risk and is it safe and effective? Ann R Coll Surg Engl. 2019 May; 101(5):353-356. doi: 10.1308/rcsann.2019.0036. PMID: 31042430; PMCID: PMC6513365.

Valdes K, Naughton N, Algar L. Usefulness of a hand therapy application. J Hand Ther. 2022 Oct-Dec;35(4):569-574. doi: 10.1016/j.jht.2021.03.007. Epub 2021 Mar 27. PMID: 34053817.



**HAYLEY FAY**

Clinical and Operational Lead Hand Therapy Digital Fellow.  
Digital Health London.  
London, UK.



### IFSHT NEWSLETTER – REACH VOLUME 3, NO. 3

Issue 3 of volume 3 of the IFSHT newsletter is now available on the IFSHT website. Please check out the following link to access it:

[https://ifsht.org/publications/?publications\\_category=29](https://ifsht.org/publications/?publications_category=29)

The publication aims to collate Research, Education, Achievement and Clinicians in Hand and upper limb therapy around the world.

In this edition of REACH we provide signposts to other sources of clinical pearls beyond the traditional book. We also continue our series on how to write and publish research.

We present new and noteworthy research on and also a glimpse of what research is coming down the line relating to hand osteoarthritis. Check out our feature article on HandyEvidence, a website that provides efficient and accessible research updates for Hand Therapists.

This issue's Spotlight On! Section features the American Society of Hand Therapists, we also continue our new "Volunteer" section and a new profile of a recipients of the prestigious IFSHT Lifetime Achievement Awards.

We call on hand and upper limb therapy clinicians and researchers to submit any contributions for consideration to: [informationofficer@ifsht.org](mailto:informationofficer@ifsht.org)



### UPCOMING EVENTS



The countdown begins! The the next Joint Triennial Congress in Washington in 2025 is just over a year away!

The website for this event is launched so please follow for updates!

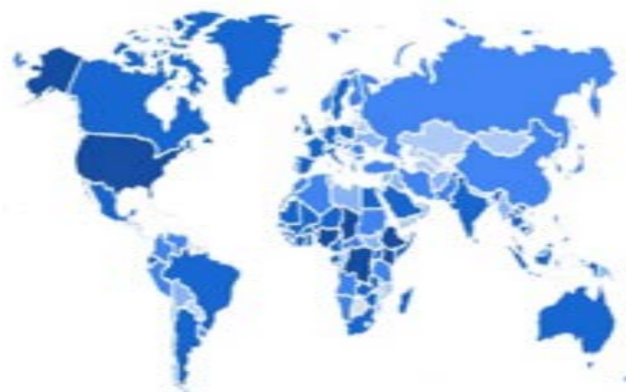<https://www.ifssh2025.org/s/>



[www.handsurgeryresource.org](http://www.handsurgeryresource.org)

#### EXCITING MERGER NEWS!

Hand Surgery Resource, with its worldwide user group, has merged with the International Federation of Societies for Surgery of the Hand (IFSSH) to further enlarge the global impact of the Federation and its new educational assets, including Hand Surgery Resource, Hand Surgery Source, Hand Surgery Primer, and our YouTube channel.



The IFSSH was founded in 1966 for the purpose of coordinating the activities of the world's hand surgery societies in view of increasing and spreading the knowledge of hand surgery around the world. The IFSSH has now grown into a large international society supporting worldwide hand surgery education on a global scale! Visit [IFSSH's website](http://www.ifssh.info) to learn more.



The educational assets of Hand Surgery Resource, and the online text, Hand Surgery Source, continue to be available at [www.handsurgeryresource.org](http://www.handsurgeryresource.org), as well as now on the IFSSH's website [www.ifssh.info/hand-surgery-resource.php](http://www.ifssh.info/hand-surgery-resource.php), and the Hand Surgery Source APP is available at the Apple Store and on Google Play.

#### TUNE INTO THE HAND SURGERY RESOURCE PODCASTS!

Subscribe to the Hand Surgery Resource podcasts! All of our podcasts are available on [Apple](#), [Google](#), [Spotify](#) and [Amazon Podcasters](#).

Wartenberg's Sign  
Ganglion Cysts  
Dupuytren's Disease  
Adult Hand Trigger Finger  
De Quervain's Disease / De Quervain's Tenosynovitis  
Carpal Tunnel Syndrome  
Pediatric Trigger Thumb or Congenital Trigger Thumb  
Osteoarthritis of the Carpometacarpal (CMC) Joint of the Thumb  
Gamekeeper's Thumb - Podcast  
Mallet Finger  
Mucoid Cysts

Tune in and let us know what you think!

#### HAND SURGERY SOURCE APP VERSION 5.0 COMING SOON

An exciting new Hand Surgery Source APP Version 5.0 is under construction and will be launched by Hand Surgery Resource in early 2024!

This new version will have improved search function and updated design to facilitate easy access to our extensive content, including our new Hand Therapy Library, while maintaining our special tools like Hand Surgery Source's read-it-to-me function.

If you haven't already, get the current Hand Surgery Source App from the [Apple store](#), [Google Play](#), or at Hand Surgery Resource at [www.handsurgeryresource.org](http://www.handsurgeryresource.org).





### IFSHT EVELYN MACKIN CONGRESS GRANT

The IFSHT Executive Committee wishes to inform you of the following Congress grant opportunity.

This triennial congress grant was established in 2010 to honour Evelyn Mackin, the first president of IFSHT and a leader in the development of hand therapy worldwide.

This grant supports an emergent hand therapist from a country without a formal hand therapy association / not a Full member of IFSHT. The recipient is someone who is a potential leader of hand therapy in their country, who may otherwise not have the resources to attend. Applicants for this grant must not be receiving funds from another source.

The recipient of this grant is fully funded to attend the IFSHT Triennial Congress; providing an opportunity to further expand their knowledge and networking in hand therapy. The recipient receives all expenses paid to attend the IFSHT Triennial Congress in Washington, DC, USA.

The recipient is identified at the IFSHT Triennial Congress, in IFSHT publications, and on the IFSHT website as the Evelyn Mackin Triennial Grant recipient.

#### PRESIDENT

Peggy Boineau

USA

[president@ifsht.org](mailto:president@ifsht.org)

#### PRESIDENT-ELECT

Stacey Doyon

USA

[presidentelect@ifsht.org](mailto:presidentelect@ifsht.org)

#### SECRETARY-GENERAL

Marie Eason Klatt

CANADA

[secretarygeneral@ifsht.org](mailto:secretarygeneral@ifsht.org)

#### TREASURER

Elizabeth Ward

AUSTRALIA

[treasurer@ifsht.org](mailto:treasurer@ifsht.org)

#### INFORMATION OFFICER

Susan de Klerk

SOUTH AFRICA

[informationofficer@ifsht.org](mailto:informationofficer@ifsht.org)

#### PAST-PRESIDENT

Nicola Goldsmith

UNITED KINGDOM

[pastpresident@ifsht.org](mailto:pastpresident@ifsht.org)

#### ELIGIBILITY

The grant is given to a Physical or Occupational Therapist working in a country that is not a Full or Associate Member in IFSHT. The therapist must have demonstrated one or more of the following:


- A strong interest in Hand Therapy.
- Efforts to specialize in Hand Therapy.
- Leadership in developing Hand Therapy as a specialty practice area in his/her country.
- Preference is given to those whose economic status makes self-funding challenging/impossible.
- Candidates must have basic written and spoken English comprehension to assist in the application process and to understand and communicate with others at the IFSHT Triennial Congress.
- The selected grant recipients agree to attend the IFSHT Congress in its entirety.
- The recipient is only eligible for receipt of this grant once.

#### IDENTIFICATION OF GRANT CANDIDATES

- Hand Surgeons who are members of IFSSH but are without an organized Hand Therapy society in their country may nominate candidates
- Grant candidates can be from countries who are Corresponding Members of IFSHT (with preference given to countries with financial challenges)
- Hand therapists who have visited and/or worked with hand therapists in a qualifying country may nominate a candidate.


To access IFSHT website for further information on the Evelyn Mackin Congress Grant use the link below. (Please note that you must be logged into the IFSHT website to apply. Please create an account or log in.)

[IFSHT EVELYN MACKIN CONGRESS GRANT](#)




The Hong Kong Society for Surgery of the Hand 36<sup>th</sup> Annual Congress

# OCCUPATIONAL & RECREATIONAL HAND DISORDERS




**DATE**  
Congress  
23 - 24 March 2024  
Workshop  
24 March 2024  
1330 - 1700  
*(please refer to separate poster for details)*

**GUEST SOCIETY**  
 **Schweizerische Gesellschaft für Handchirurgie**  
*(Swiss Society of Hand Surgery)*

**VENUE**  
Faculty of Medicine,  
The University of Hong Kong  
*Cheung Kung Hai Conference Centre,  
G/F, William MW Mong Block,  
21 Sassoon Road, Pokfulam, Hong Kong*

**Co-organized by:** Hong Kong Society for Surgery of the Hand  
Department of Orthopaedics & Traumatology, School of Clinical Medicine,  
LKS Faculty of Medicine, University of Hong Kong





# 17<sup>th</sup> ANNUAL CONFERENCE

OF THE EGYPTIAN SOCIETY FOR SURGERY OF THE HAND AND MICROSURGERY (ESSHM)



**06-08 March 2024**  
Triumph Plaza Hotel, Cairo

*In collaboration with*  
**African Society for Surgery of The Hand**

**Choice, Controversies, and Complications [CCC]**  
[www.esshm.net](http://www.esshm.net)

Conference President  
**RAMY EI NAKEEB**

Conference Secretary General  
**MOHAMED A. ELLABAN**

Head of Scientific Committee  
**RASHED EMAM**

Head of Organizing Committee  
**AHMED FATHY SADEK**

African Society National Delegate  
**AMR ALI**

**ORGANIZING COMMITTEE**

Abd Elhakim Abdallah	Hany Morsi	Mostafa Mahmoud
Ahmed Naeem Atiyya	Hassan El Noamany	Nash Naam
Ahmed Sobhi Hweidi	Magdy Nabil	Tarek Abdallah Elgammal
Amr Elsayed	Maged El Shennawy	Yasser Safoury
Ashraf Moharram	Mohamed Elmahy	Yehia Basiony
Essam Elkaref	Muhammad Reda Ahmad	



ÖSTERREICHISCHE GESELLSCHAFT FÜR  
**HANDCHIRURGIE**  
**KLAUSURTAGUNG 2024**  
gemeinsam mit der  
Österreichischen Gesellschaft für Handtherapie (ÖGHT)  
15. - 16. MÄRZ 2024 | LINZ

**BSSH** The British Society for  
Surgery of the Hand  
**2024 SPRING  
SCIENTIFIC MEETING**  
25 - 26 April 2024, Royal Armouries, Leeds



2024 COMBINED MEETING  
OF THE AMERICAN SOCIETY FOR SURGERY OF THE HAND AND THE AUSTRALIAN HAND SURGERY SOCIETY

**INNOVATIONS**  
ACROSS THE PACIFIC *in* HAND SURGERY  
MAY 2-4, 2024  
THE WESTIN MAUI RESORT & SPA, KA'ANAPALI

*Maui, Hawaii*




**HAND IN THE THEATER**  
LOUVAIN HOUSE  
TUE 21/05 - 18.00-23.00



belgian  **handgroup** spring congress 2023



**50**  
ANIVERSARIO  
1974 - 2024

**48° CONGRESO**  
ARGENTINO DE CIRUGIA DE  
LA MANO Y RECONSTRUCTIVA  
DEL MIEMBRO SUPERIOR

**25° CONGRESO**  
DEL CAPITULO ARGENTINO  
DE TERAPIA DE LA MANO

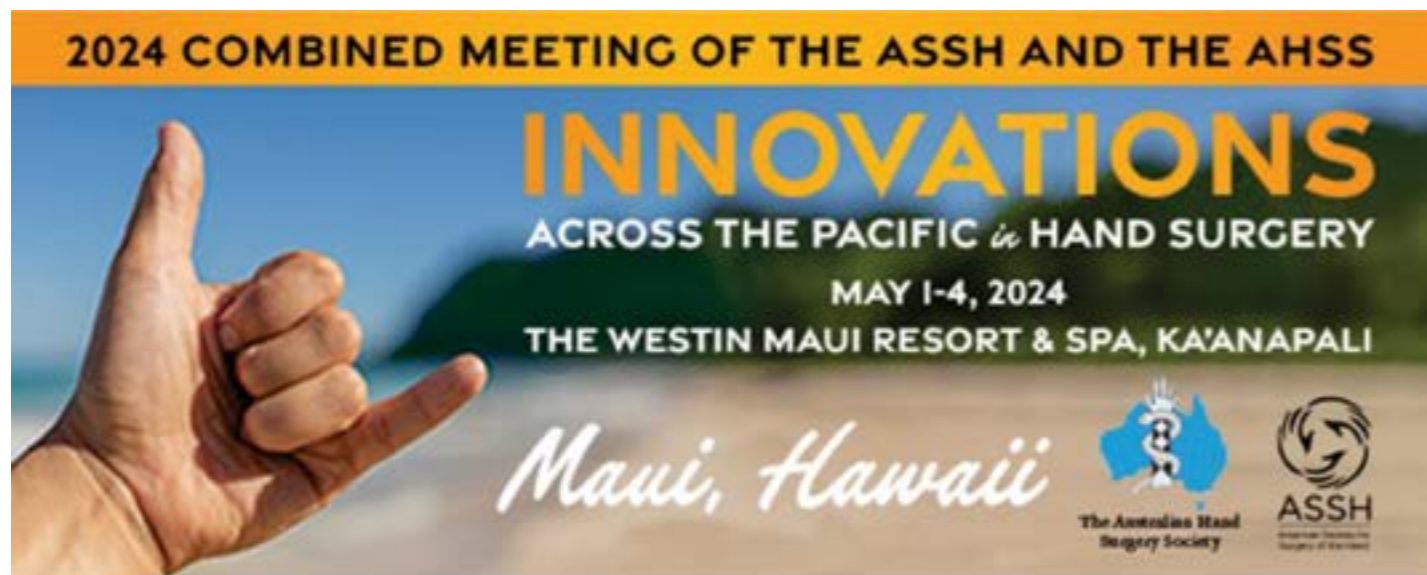**MAR DEL PLATA**  
SHERATON HOTEL

NACIÓN INVITADA  
ESPAÑA

**6-7-8**  
NOVIEMBRE

**2024**

[aacmyrms.org](http://aacmyrms.org)



**Join us in Maui for Innovations Across the Pacific in Hand Surgery**

**Wednesday, May 1 - Saturday, May 4, 2024  
The Westin Maui Resort & Spa, Ka'anapali**

The 2024 Innovations Across the Pacific in Hand Surgery Conference is a combined meeting between the American Society for Surgery of the Hand and Australian Hand Surgery Society. Fostering the collaborative spirit between the two societies, this meeting is designed to challenge dogma and present exciting advancements in hand and upper extremity surgery.

**Thursday Sessions:**

- Scaphoid Nonunion
- Distal Radius Fractures
- Ulnar Wrist Pain
- Carpal Instability
- Management Considerations in the Rheumatoid Arthritis Patient

**Friday Sessions:**

- Innovation in Hand Surgery
- Peripheral Nerve Injuries
- ASSH vs AHSS (Quiz Bowl)
- Basilar Thumb Joint Arthritis
- Spasticity
- Tendon Injuries
- Dupuytren's disease
- Mangled Hand
- Sports Injuries and Return to Play

**Saturday Sessions:**

- Hand Fractures
- Tissue Reconstruction
- Wrist Arthroscopy
- Congenital
- MR, RPNI & Prosthetics
- Kienbock's Disease
- Elbow Disorders
- Compression Neuropathies



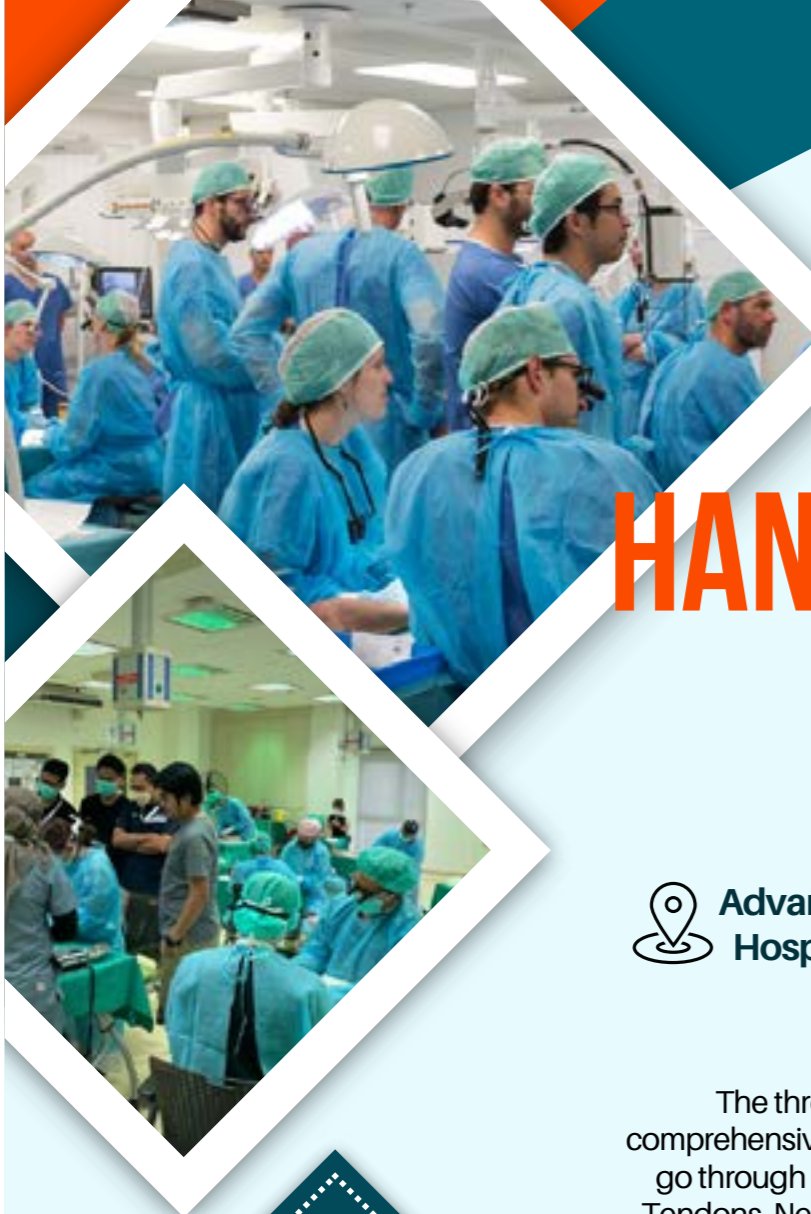## 67<sup>th</sup> ANNUAL MEETING OF THE JAPANESE SOCIETY FOR SURGERY OF THE HAND

**APRIL 25-26, 2024, NARA, JAPAN**

### Functional Anatomy and Innovation in Hand Surgery

Venue	Nara Prefectural Convention Center, JW Marriott Hotel Nara, JAPAN.
President	Shohei OMOKAWA, MD.

<https://naraseikei.com/67jssh/>



Organised by:



# ESSER ASIA HAND SURGERY COURSE

1 - 3 March 2024

**Advanced Surgical Skills Centre (ASSC)**  
Hospital Canselor Tuanku Muhriz UKM  
56000 Cheras  
Kuala Lumpur, Malaysia

The three day Esser Asia Hand Surgery Course is a comprehensive course where you as a hand surgeon will go through the four most important topics: Local Flaps, Tendons, Nerves and Fractures. This course is designed with theoretical and practical sessions on fresh frozen cadavers with two participants per cadaver.

**24**  
PARTICIPANTS  
MAX

**USD 996**

REGISTER NOW

## TOPICS

- Local Flaps
- Nerves
- Tendons
- Fractures

Visit Our Website

<https://essermasterclass.com/hand-surgery-course-asia/>



Contact Us  
**+6012-695 0234**



**SAVE THE DATE**

**5<sup>TH</sup> EUROPEAN SYMPOSIUM ON PEDIATRIC HAND SURGERY AND REHABILITATION**

**Rotterdam**

More information at: [www.kinderhand.net](http://www.kinderhand.net)

Preceding the FESSH meeting:  
**25-26 June 2024**

TAIWAN SOCIETY FOR SURGERY OF THE HAND

4-5 MAY 2024

**2024**

ANNUAL MEETING OF THE TSSH

KAOSHIUNG MEDICAL UNIVERSITY CHUNG-HO MEMORIAL HOSPITAL





# 2024



## XXVII Congreso Secma

24 - 26 de abril 2024 / Sitges

SOCIEDAD ESPAÑOLA DE CIRUGÍA DE LA MANO

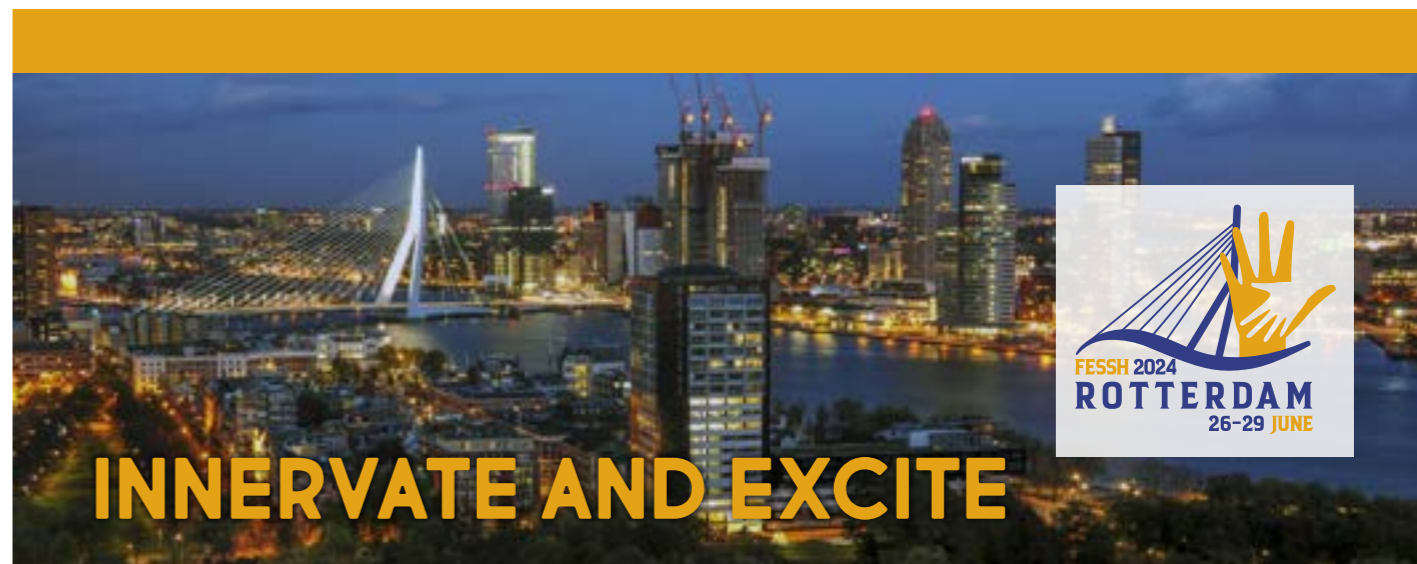SEDE: Hotel Meliá Gran Sitges - Presidente del Congreso: Dr. Joaquim Casañas Sintés

SECRETARÍA TÉCNICA: ATENTA MARKETING

<https://atenta.es/>

[secma@secma.es](https://secma@secma.es)

[congresosecma2024.com](https://congresosecma2024.com)



## INNERVATE AND EXCITE

Registration is open!

<https://fessh2024.com/>

## JOIN US AT FESSH 2024 IN ROTTERDAM

We are very pleased to invite you to the 2024 FESSH meeting in Rotterdam, The Netherlands. Theme of the congress is **peripheral nerve surgery**. The program will have sessions with European Journal of Hand Surgery, several instructional courses, case discussions, workshops, the traditional arthroscopy session and live CadLab surgery sessions. The social program will include the FESSH Party on very trendy location.

### Rotterdam is

the largest harbor in Europe,  
a vibrant city with great cuisine,  
exquisite art and an impressive skyline.  
It is easy to reach by air  
(Amsterdam Schiphol), train and car.



FESSH  
Federation of  
European Societies for  
Surgery of the Hand

Congress President:  
Brigitte van der Heijden



Nvvh

Congress President:  
J. Henk Coert

See you there this June!



XXX. FESSH CONGRESS

June 25 - 28, 2025  
Helsinki, Finland  
Jorma Ryhänen

[fessh2025.com](https://fessh2025.com)



XXXI. FESSH CONGRESS

June 03 - 06, 2026  
Basel, Switzerland  
Esther Vögelin, Philipp Honigmann

[fessh2026.com](https://fessh2026.com)



XXXII. FESSH CONGRESS

2027  
Prague, Czech Republic  
Ales Fibr, Radek Kebrle

[fessh2027.com](https://fessh2027.com)

# Re-published Article

## THALIDOMITE REVIEW



Review Article

**JHS(E)**

## Thalidomide upper limb embryopathy – pathogenesis, past and present management and future considerations

Neil Vargesson<sup>1</sup> , Geoffrey Hooper<sup>2</sup>, Grey Giddins<sup>3</sup>,  
Alastair Hunter<sup>4</sup>, Paul Stirling<sup>5</sup> and Wee Lam<sup>6</sup>

Journal of Hand Surgery  
(European Volume)  
2023, Vol. 48(8) 699–709  
© The Author(s) 2023



Article reuse guidelines:  
sagepub.com/journals-permissions  
DOI: 10.1177/17531934231177425  
journals.sagepub.com/home/jhs

 Sage

### Abstract

This review article provides a comprehensive overview of thalidomide upper limb embryopathy including updates about its pathogenesis, a historical account of the management of the paediatric thalidomide patient, experience with management of the adult patient, as well as creating awareness about early onset age-related changes associated with limb differences. Despite its withdrawal from the market in November 1961, novel discoveries have meant thalidomide is licensed again and currently still in use to treat a variety of conditions, including inflammatory disorders and some cancers. Yet, if not used safely, thalidomide still has the potential to cause damage to the embryo. Recent work identifying thalidomide analogues that retain clinical benefits yet without the harmful effects are showing great promise. Understanding the problems thalidomide survivors face as they age can allow surgeons to support their unique healthcare issues and translate these principles of care to other congenital upper limb differences.

### Keywords

Thalidomide, radial dysplasia, reversed shoulder, embryopathy, cereblon

Date received: 24th April 2023; revised: 27th April 2023; accepted: 4th May 2023

### Introduction

Thalidomide was marketed in several countries worldwide as a sedative between 1957 and 1962, and rapidly gained popularity as an effective drug for relieving morning sickness in expectant mothers. No screening was undertaken in humans prior to approval by drug licensing authorities, although drug screening in animal models demonstrated apparent drug safety. In the early 1960s, it was suggested that an increase in the number of congenital abnormalities may be linked to maternal ingestion of thalidomide (Lenz, 1962; McBride, 1961). The evidence continued to grow and by late November 1961, when thalidomide was withdrawn from the market, the teratogenic effects of thalidomide were indisputable (Vargesson, 2019; Vargesson and Stephens, 2021).

One of the most striking teratogenic effects of thalidomide was seen in the upper limbs, with congenital upper limb differences occurring in up to 87% of thalidomide survivors (Mansour et al., 2019).

These ranged from milder conditions like Blauth II or III thumb hypoplasia, to Bayne IV radial dysplasia with complete thumb absence and in the most severe cases, phocomelia and amelia. Upper limb thalidomide embryopathy was typically bilateral and more severe in the left than right upper limb, for reasons unknown. In addition to the upper limbs, most other

<sup>1</sup>School of Medicine Medical Sciences & Nutrition, Institute of Medical Sciences, University of Aberdeen, Aberdeen, UK

<sup>2</sup>Princess Margaret Rose Orthopaedic Hospital, Edinburgh, UK

<sup>3</sup>Royal United Hospitals, Bath, UK

<sup>4</sup>Department of Trauma and Orthopaedics, University College London Hospitals, London, UK

<sup>5</sup>Fife Hand Clinic, Queen Margaret Hospital, Dunfermline, UK

<sup>6</sup>Royal Hospital for Children and Young People, Edinburgh, UK

### Corresponding Author:

Neil Vargesson, School of Medicine Medical Sciences & Nutrition, Institute of Medical Sciences, University of Aberdeen, Aberdeen AB25 2ZD, UK.

Email: n.vargesson@abdn.ac.uk

tissues and organs in the body could be affected, leading to lower limb abnormalities, hearing problems, micro-ophthalmia, spinal issues, internal organ damage or damage to the cardiovascular, renal and gastrointestinal systems (Mansour et al., 2019; Vargesson, 2019).

Many lessons have been learned from this tragedy, which affected thousands of newborns, in the late 1950s and early 1960s, and their families. Many of those who survived were treated surgically as children. These survivors are now aged between 59 and 64 years, and some are experiencing early onset age-related changes in adjacent joints with further adverse effects on their quality of life (Markiewicz et al., 2023).

In this article, we provide an update on the pathogenesis of thalidomide upper limb embryopathy and a historical account of upper limb management in affected patients. We also reassess the present management of patients, especially as they reach their seventh decade of life with age-related problems. It is hoped that this article will provide some important pointers for the future management of these patients and also allow us to revisit lessons learned from this tragedy.

### Update of the pathogenesis and mechanism of thalidomide embryopathy

Thalidomide has numerous actions on the body. It has anti-inflammatory, immunomodulatory, anti-angiogenic and anti-myeloma actions as well as actions on the nervous system, where it can be neuroprotective as well as cause peripheral neuropathy after long-term exposure (Vargesson, 2019). Given these actions, thalidomide and its sister analogues lenalidomide and pomalidomide, are now used as effective treatments for several conditions, including multiple myeloma and the complications of leprosy (Vargesson, 2019). Thalidomide has also been shown to effectively treat vascular disorders, including hereditary haemorrhagic telangiectasia (HHT) (Lebrin et al., 2010; Peng et al., 2015), small bowel vascular malformations (Tang et al., 2020) and recently, radiation induced brain inflammation (Cheng et al., 2023). Thalidomide is known to be broken down into active metabolites either by spontaneous hydrolysis in body fluids or through the cytochrome P450 enzyme system in the liver (Franks et al., 2004; Vargesson, 2015). With thalidomide in clinical use and its teratogenic effects still present, great care must be taken when administering the drug to patients; patient protection schemes are in place in many areas of the world to ensure it is taken and used

safely (Mueller and Lewis, 2021). The need for such schemes is emphasized by recent reports of cases of thalidomide embryopathy in Brazil, where thalidomide is used to treat endemic leprosy (Vianna et al., 2011).

It is well known that thalidomide causes damage to the upper limbs and other external tissues of the body (i.e. face, ears, eyes, genitals, etc.) in a short time sensitive window in the first trimester of human development. How does thalidomide cause birth differences? Recent research indicates that there are three favoured models of how thalidomide causes damage to the forming embryo, however these are unlikely to be mutually exclusive.

### Cereblon

Cereblon (CRBN) is a ubiquitin ligase whose role is to tag other molecules for destruction when they are no longer required. Cereblon is bound by thalidomide to form a complex; recent experiments demonstrated that when exposed to engineered versions of cereblon that cannot bind thalidomide, zebrafish and chicken embryos remained unaffected by the modified version of thalidomide (Ito et al., 2010). Since this finding, the cereblon–thalidomide complex has been found to bind to and modulate the expression of other genes, including Ikaros and Aiolos, which are involved in the anti-myeloma action of thalidomide but also in repressing the expression of molecules, such as SALL4, p63 and PLZF, among others that have important functions in limb development (Asatsuma-Okumura et al., 2019, 2020; Donovan et al., 2018; Matyskiela et al., 2018; Yamanaka et al., 2021). Moreover, in humans who possess SALL4 genetic variations, this leads to Duane-radial ray syndrome, in which there are limb and internal organ differences that can look remarkably similar to thalidomide embryopathy, and which has been confused with this condition (Kohlhase et al., 2004, 2005). To date, it has not been conclusively demonstrated that SALL4 is responsible for all the damage seen in thalidomide survivors and birth differences between thalidomide embryopathy and Duane-radial ray syndrome do differ. Nonetheless, the fact that multiple different genes have now been linked to the cereblon–thalidomide complex indicates that thalidomide is likely to influence multiple gene targets and pathways in timing-dependent ways (Asatsuma-Okumura et al., 2020; Vargesson, 2019).

### Induction of cell death and reactive oxygen species

Thalidomide can induce cell death in embryonic tissues and also prevent cell proliferation

(Knobloch et al., 2007, 2011). It has also been shown to induce reactive oxygen species, which themselves can lead to cell death causing tissue damage. Moreover, preventing embryos from producing reactive oxygen species makes the embryos resistant to thalidomide embryopathy (Parman et al., 1999).

### Inhibitory action on the blood vessels

In chicken embryos the anti-angiogenic action of thalidomide has been shown to cause rapid blood vessel loss, induce cell death and cause a range of limb differences that look remarkably similar to those in thalidomide-exposed humans (Davey et al., 2018; Therapontos et al., 2009). The other known actions of thalidomide, namely anti-inflammatory and neurotoxic actions, do not seem to harm the development of the chicken embryo (Mahony et al., 2018; Therapontos et al., 2009).

Ongoing work in this area has identified many vascular specific molecular targets that are influenced by thalidomide (Ema et al., 2010; Vargesson, 2015; Yabu et al., 2005). Vasoprotective agents such as nitric oxide can prevent thalidomide-induced antiangiogenic actions (Siamwala et al., 2012; Tamilarasan et al., 2006). Importantly, thalidomide seems to target newly formed or developing blood vessels that do not possess a protective vascular smooth muscle coat, whereas those that possess a smooth muscle coat are unharmed and develop normally (Therapontos et al., 2009; Vargesson and Hootnick, 2017). In early limb and embryonic development, there are more smooth muscle negative vessels present which are susceptible to damage by thalidomide, while later in limb and embryonic development blood vessels are mature with smooth muscle coats and therefore thalidomide damage is much less severe (Therapontos et al., 2009; Vargesson, 2015, 2019). Thus, the range of limb differences (and other embryonic damage) induced by thalidomide could be attributed to the timing of exposure and blood vessel maturity.

Notwithstanding that limb development outgrowth and patterning is controlled by important molecules, such as Fibroblast Growth Factor 8 (Fgf8) and Sonic Hedgehog (Shh), respectively, and that both these molecules have been shown to be downregulated by thalidomide in chicken, zebrafish and rabbit studies, it remains unclear if this action is direct or indirect (for example through vascular inhibition and tissue loss) (Hansen et al., 2002a, 2002b; Ito et al., 2010; Knobloch et al., 2011; Therapontos et al., 2009).

The longer-term effects of vascular damage remain areas of current research interest.

For example, it can be difficult in some thalidomide patients to palpate a pulse in the arms and take blood pressure readings as the vascular patterns are altered (Tajima et al., 2016). Mechanistically this is likely, either, (i) because the vessels did not form and are not there or are in different locations, with the resulting tissue damage causing further changes to vascular patterning events and further exacerbating the damage. Or (ii) the vascular abnormalities and changes could be secondary to loss of molecules like SALL4, p63, PLZF (and others) causing loss of cells or failure of cells to proliferate, migrate and differentiate into the correct tissues in the correct places. The resulting limb damage would then be exacerbated by loss or misplacement of blood vessels and later in development, by nerve innervation being altered as a result of the tissue loss. Alternatively (and more likely in the opinion of the Authors) it may be caused by both of the above mechanisms, and which is dependent on the timing of limb/embryo development and exposure to thalidomide.

### Recent updates

Recent work indicates that the anti-angiogenic action of thalidomide can also occur in a cereblon-independent manner, highlighting that the action of thalidomide on the blood vessels could be direct as well as through other molecular targets (Beedie et al., 2020; Heim et al., 2021; Peach et al., 2020). Indeed, recent research indicates that cereblon, p63, SALL4, EGFL6 are expressed in, or have roles in, the development of blood vessels, suggesting thalidomide could influence these molecules in developing vessels (Beedie et al., 2020; Chandrangsu and Sappayatosok, 2016; Tang et al., 2020). Whether these molecules also underpin the anti-angiogenic action of thalidomide directly remains unknown.

Furthermore, it has been known for a long time that thalidomide is broken down into active metabolites in two ways, either through the cytochrome P450 (CYP2C19 and CYP3A) enzyme pathway in the liver, or by hydrolysis in body fluids (Chowdhury et al., 2010; Franks et al., 2004; Yamazaki et al., 2012). Previous work has indicated that some of these active metabolites could be causing some of the actions of thalidomide; for example, metabolic activation seems to be required for the drugs anti-angiogenic action and its teratogenic action (Bauer et al., 1998; Franks et al., 2004; Vargesson, 2013). Indeed, recent work has shown that the damage caused by thalidomide in zebrafish embryos is more pronounced in those expressing human cytochrome P450 enzymes (CYP3A), indicating that the

cytochrome P450 pathway [which breaks down thalidomide] may be responsible for the teratogenic actions of thalidomide in humans (Dong et al., 2023). This has been further demonstrated by recent work showing a major metabolite of thalidomide, 5-hydroxythalidomide, was identified to bind cereblon and form a CRBN-SALL4 complex leading to SALL4 degradation, which has been linked with some of the teratogenic actions of thalidomide [see earlier section]. While thalidomide itself induced the formation of a CRBN-Ikaros complex only; with Ikaros underpinning the drug's immunomodulatory actions (Furihata et al., 2020). These findings would suggest the ability of thalidomide and its metabolites to form CRBN complexes with different molecules, may underpin some or many of the different actions/functions of thalidomide. Yet, as discussed, thalidomide's antiangiogenic action can also harm the embryo and also occur in a cereblon independent manner (Beedie et al., 2020; Heim et al., 2021; Peach et al., 2020). When taken altogether, this then might explain the pleiotropic and variable nature of the damage seen between survivors through thalidomide potentially utilizing multiple mechanisms of action in the embryo. Indeed, we know thalidomide has many clinically relevant actions in the adult, including anti-inflammatory, anti-myeloma, anti-angiogenic as well as neuroprotective actions, and which would likely be devastating in the developing embryo.

In summary, while great progress has been made in the last few years in our understanding of the mechanism underlying thalidomide upper limb embryopathy, the precise mechanism remains to be determined. It is likely that the cereblon pathway, the ability of the drug to induce cell death, inhibit cell proliferation and its antiangiogenic actions, are all involved. The search for the exact mechanisms continues and remains as important as ever as we see ongoing or new medical issues in thalidomide patients who are experiencing early onset age-related changes, such as neuropathy (Markiewicz et al., 2023). The rest of the article examines some of the past and present clinical management of these patients.

### Early management of the paediatric patient with a focus on surgery and prostheses

Many of the thalidomide-affected infants who survived in the 1950s and 1960s had upper limb anomalies of various types but tending to be of the most severe kind. Absence of the upper limb, vestigial

digits attached to the shoulder, flipper-like limbs and various forms of radial dysplasia were all seen. Most children had both their upper limbs affected in a similar pattern. In addition, many with upper limb anomalies also had very severe lower limb deficits, and problems with sight and hearing as well as gut and cardiac anomalies. The management of the upper limb problems could be seriously affected by these associated conditions.

There were few centres in the 1960s and 1970s that had the expertise to deal with the onslaught from these severe congenital problems, which had previously been rare. In Scotland, the Princess Margaret Rose Orthopaedic Hospital (now closed) in Edinburgh became a national referral centre because the necessary surgical expertise was available. A bioengineering centre was established for the development and fitting of prosthetic limbs and appliances, both for upper and lower limb problems. A self-care unit allowed the children and their parents to stay in the hospital while being assessed by surgeons, prosthetists, occupational therapists and physiotherapists; this was important because many of the children had come from a long distance away, and time was required to assess their needs. The multidisciplinary approach was essential.

The therapists had an important role in teaching the children to use simple adaptations and appliances for self-care activities, such as dressing and perineal hygiene, and to use the mouth for holding and manipulating objects (Figure 1). Initially it was thought that powered prostheses would help in the management of upper limb problems in children affected by thalidomide, but the upper limb prostheses then available, either cord operated or gas powered, had almost no role to play in improving upper limb function (Nichols et al., 1968). They were too cumbersome and children who had relatively good function in the lower limbs rapidly learned to use

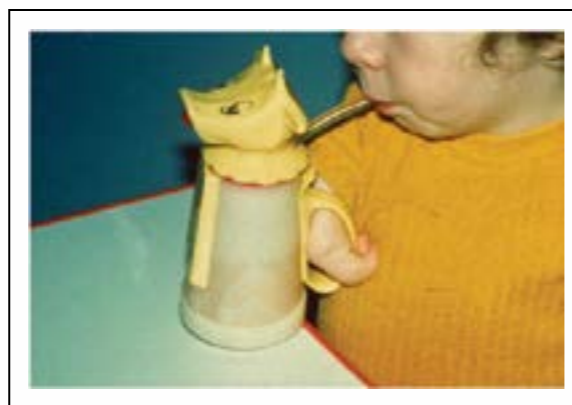

Figure 1. Simple orthoses could help with daily activities.

their legs and feet for functions normally carried out with the arms and hands, usually with great dexterity.

Clearly no surgical treatment was appropriate for a missing limb, or a vestigial digit attached to the trunk, although the latter structure might be used to operate a switch on a powered prosthesis. There was a small place for passive, cosmetic prostheses to fill the clothes of those with completely missing upper limbs.

In addition, the nomenclature for congenital hand differences was very much in development during the thalidomide era. The term 'phocomelia' was commonly applied to any anomaly in which a recognizable but highly abnormal hand was attached to the shoulder region. The clavicle was present and usually normal, and there was a scapula, but the shoulder joint itself was always absent, meaning that the hand was not stable on the trunk (Lamb et al., 1971) (Figure 2). Re-examination of radiographs from these 'phocomelic' upper limbs has shown that almost none of them had the standard types of intercalary deficits described by Frantz and O'Rahilly (1961) before the thalidomide tragedy; most were extreme forms of longitudinal defects (Goldfarb et al., 2005; Tytherleigh-Strong and Hooper, 2003). These short and unstable upper limbs were of little functional use, especially if they were too short to come together within the child's visual field; such grasping movements using both upper limbs are one of the first purposeful ones made by an infant. Attempts were made to overcome this problem surgically by combining stabilization of the hand with lengthening the upper limb. This was done by mobilizing the clavicle from its sternal attachment and turning it down to attach it to the hand, producing a rudimentary shoulder and with some potential for growth in the upper

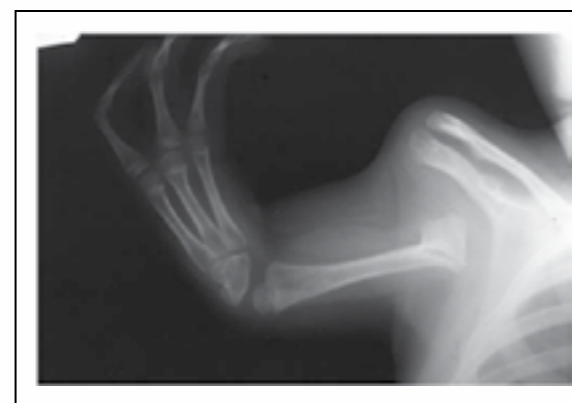


Figure 2. A typical example of thalidomide-associated 'phocomelia'. Note the presence of the scapula and clavicle. The hand has a major radial deficit and is attached to a short bone that has some features of a humerus.

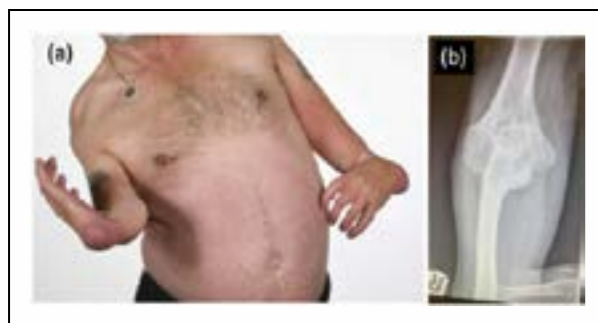limb (Sulamaa and Ryöppy, 1964). Although the originators reported encouraging early results, the procedure did not come into wider use and the non-surgical alternatives of therapeutic training were probably more effective.

Where surgery did have a major role was in the treatment of the various forms of radial dysplasia, one of the characteristic types of upper limb anomaly in those affected by thalidomide. Much experience was gained in the management of radially deviated hands, by centralization (Lamb, 1977) and radialization (Buck-Gramcko, 1985) of the hand on the wrist, and in the treatment of absent thumbs by pollicization (Buck-Gramcko, 1971). Although doubt has been cast on the utility of wrist realignment procedures (Ezaki, 2021), a longer-term follow-up of adult patients treated by centralization (most with added pollicizations) in childhood found that their function was generally good (Lamb et al., 1997). However, the forearms were short and there was usually some recurrence of radial deviation. Other less common upper limb anomalies associated with thalidomide were treated on an individual basis.

The thalidomide tragedy brought undue suffering, but the management of these children via a one-stop multidisciplinary centre allowed some hope and respite to many children and their families. The longer-term study (Lamb et al., 1997) also found that many children grew up to be well-adjusted adults who had married in their 20s and 30s and had children of their own, and most were gainfully employed. Nevertheless, the longer-term effects of thalidomide on the upper limb remains unknown as these adults reach their seventh decade of life.

### Age-related problems in upper limb thalidomide embryopathy

Ruffing (1977) reported on a series of children with thalidomide embryopathy and introduced the concept of 'hidden defects', differences that were not immediately obvious on clinical presentation that may only become apparent with the passage of time. It was specifically noted that 'early osteoarthritis is expected to occur in the future'. For example, with a missing radius, forearm rotation is affected, and the elbow is often stiff (Figure 3). The younger patient can compensate by constant excessive external rotation at the shoulder, but over time this may result in damage to the glenohumeral joint, leading to glenoid dysplasia and concave remodelling of the humeral head. The overall effect of this remodelling is to move the centre of rotation of the glenohumeral joint inferiorly and medially, optimizing the deltoid

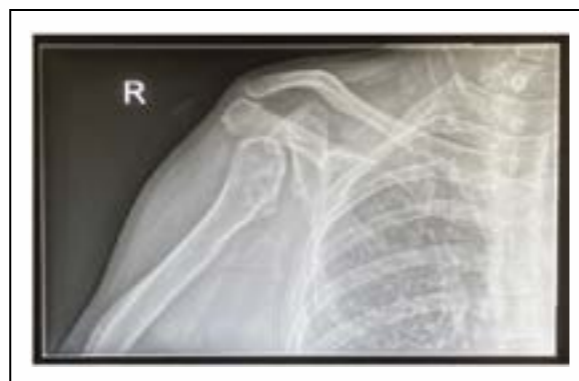

**Figure 3.** (a) An adult thalidomide patient with bilateral radial dysplasia. (b) The right elbow joint, demonstrating a single bone articulation that can be compensated for by glenohumeral external rotation.

muscle lever arm for improved glenohumeral stability and function. These are the same principles that are harnessed in reverse geometry shoulder arthroplasty, and this pattern of change has been described as development of a 'natural' reverse shoulder replacement (Kimmeyer et al., 2021) (Figure 4).

The incidence of such 'hidden' age-related changes in these patients may be underestimated. The approximately 450 thalidomide survivors in the UK are now aged between 59 and 64, a time of onset of symptomatic degenerative musculoskeletal pathology, even for a population of this age without congenital differences. The emergence of hidden defects, combined with the cumulative effects of altered joint biomechanics with increasing age may predispose survivors to such pathology. Ghassemi Jahani et al. (2014) and Newbronner et al. (2019) found that the prevalence of arthritis is increased in thalidomide survivors as compared with the general population, affecting around 93% of patients at a mean age of 46 years. Even in their fourth decade, these survivors already showed worse patient-reported outcome measures (PROMs) as compared with baseline population values (Ghassemi Jahani et al., 2014). To our knowledge, there are no specific longitudinal studies with paired data, but comparison of PROMs between patients with a mean age of 46 in one study (Ghassemi Jahani et al., 2014) and a mean age of over 60 in another study (Markiewicz et al., 2023) revealed significantly worse function in older survivors.

The health-related quality of life (HRQoL) of survivors is also significantly worse than baseline population values. Despite increasing awareness and publication of the functional and HRQoL problems faced by survivors, up to 43% of survivors report difficulty accessing healthcare services (Nippert et al., 2002), with survey data showing that survivors



**Figure 4.** Radiological changes of the right shoulder joint showing severe glenoid dysplasia, with concave remodeling of the humeral head. This is due to constant excessive external rotation at the shoulder and has been described as a 'natural reverse shoulder replacement'.

perceive a lack of understanding of complex care needs as a significant barrier.

The hand surgery community must be mindful of the physical and social challenges faced by this group of patients to ensure ongoing appropriate care in the context of deteriorating disability. Managing the upper limb problems in this unique adult patient population will require easier and more direct access to appropriate surgical expertise. It is also important that hand surgery colleagues share their experience: although the number of referrals of these adult patients is likely to be small, it will probably increase as they age and access to care becomes more widely available.

### Management of the adult patient

As with any complex upper limb disorder, a holistic approach is emphasized in the management of the adult patient with thalidomide embryopathy. Working with multidisciplinary specialists with experience of these adult patients, including neurologists, dermatologists and therapists, is important. National organizations with extensive networks, such as The Thalidomide Trust in the UK, can provide additional support for patients and clinicians.

The most common presentations are pain, increasing restriction with activities of daily living and nerve-related symptoms, particularly carpal tunnel syndrome (Ohnishi and Hinoshita, 2017). The assessment focuses on the history of the presenting symptoms while taking into account how this affects their broader function, as pain and decreasing joint movement owing to new onset adult symptoms compound existing impairments (Newbronner and Atkin, 2018). It is important to gain a detailed understanding

of their level of independence, activities of daily living and support network in order to inform what treatment options might be practical and reliable. A surgical history will be especially relevant as most adults with thalidomide embryopathy will have had some surgery previously, the majority as children (Ghassemi Jahani et al., 2017). They will also present with the standard co-morbidities of any adult of their age, so a thorough past medical and drug history will be essential in assessing the surgical and anaesthetic risks.

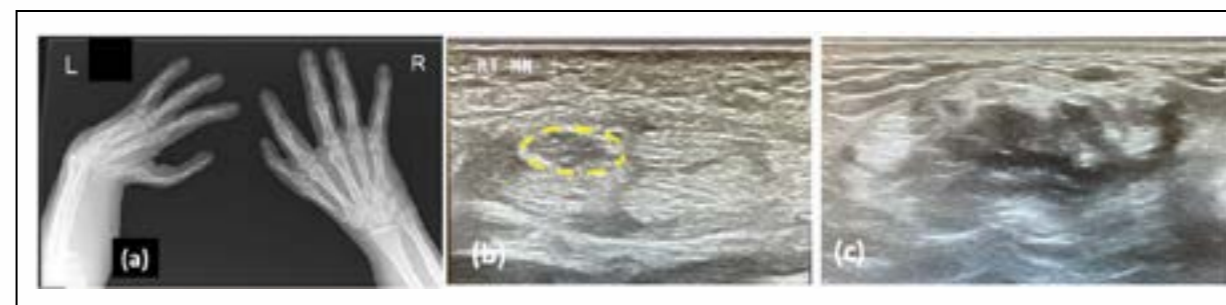
Clinical examination should encompass the entire upper limb, while taking into account any lower limb pathology. The pattern of upper limb difference is typically unique to that individual; as discussed, the commonest ones include limb shortening, radial longitudinal deficiency and asymmetry. Up-to-date nomenclature and classification of these differences should probably be used for communication with other congenital hand specialists and also to gather meaningful data, going forward (Chan et al., 2023).

The active and passive ranges of movement should be measured and recorded, and a detailed neurological examination is required especially in the presence of any evolving neurological symptoms. Generalized alterations in sensation are common in patients with thalidomide embryopathy (Nicotra et al., 2016) and may include cervical spinal nerve entrapment. A functional assessment with a physiotherapist or occupational therapist is often valuable in gaining a broader perspective on functional status and on how to optimize upper limb symptoms, especially when considering more complex upper limb surgery. The use of PROMs or other health-related questionnaires should become an established part of assessment in these patients. Radiographs should include the affected joint and possibly the entire upper limb, to allow a clear picture of the bony

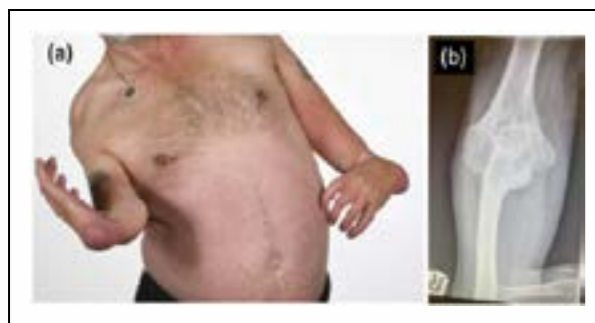anatomy and joint pathology. Gaining orthogonal views of each joint may prove difficult owing to fixed flexion deformities. Computed tomography (CT) scans are particularly helpful when assessing the patterns of deformity and planning surgery.

Nerve-related symptoms are one of the commonest presentations in adult thalidomide patients. Carpal tunnel decompression (CTD) is the most common upper limb procedure in adult patients with thalidomide embryopathy (Ghassemi Jahani et al., 2017). Deformity arising from radial longitudinal deficiency, for example extreme wrist flexion may lead to an increased risk of median nerve compression at the wrist (Figure 5). Various studies suggest the drug can also cause a direct axonal injury that is dose-dependent (Zara et al., 2008). Reports of patients who developed late-onset neuropathy after ingesting thalidomide as adults would also suggest there is a direct neurotoxicity. Rose et al. (2005) reported two adult patients, one treated with thalidomide for myeloma and the other for Behçet disease who developed lower limb neuropathy and were successfully treated with decompression operations. The proposed mechanisms include inhibition of TNF-alpha and NF-Kappa-B, which are required for sensory nerve survival (Mileshkin and Prince, 2006; Umaphathi and Chaudhry, 2005); in addition, capillary damage from long-term exposure to thalidomide resulting in axonal cell death has also been proposed (Grammatico et al., 2016). Further research in this area should yield important insights in the pathogenesis of this common side effect.

In patients with peripheral nerve-related symptoms, nerve conduction studies should be done, ideally by a neurophysiologist with experience of adult thalidomide patients. A mixed picture of nerve compression and polyneuropathy is often found, but if there is a congenital difference with altered wrist



**Figure 5.** (a) This patient with bilateral radial dysplasia presented with severe median nerve compression in his right hand. Note the scaphoid hypoplasia on the right wrist indicating a mild radial dysplasia with thumb hypoplasia. (b) Ultrasound images showed an enlarged median nerve proximal to the carpal tunnel (yellow dotted line). Such imaging is helpful when planning surgery as the position of the nerve may be abnormal and (c) The left wrist was also scanned but no median nerve could be seen convincingly.

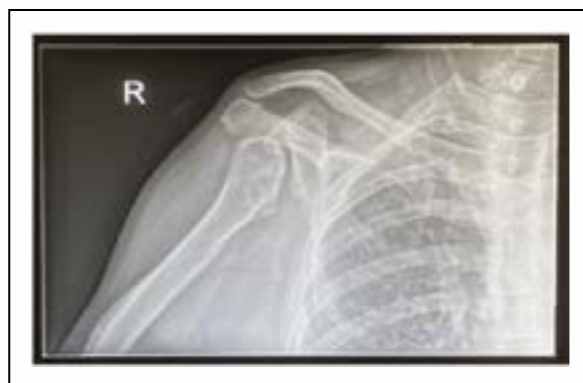

**Figure 3.** (a) An adult thalidomide patient with bilateral radial dysplasia. (b) The right elbow joint, demonstrating a single bone articulation that can be compensated for by glenohumeral external rotation.

muscle lever arm for improved glenohumeral stability and function. These are the same principles that are harnessed in reverse geometry shoulder arthroplasty, and this pattern of change has been described as development of a 'natural' reverse shoulder replacement (Kimmeyer et al., 2021) (Figure 4).

The incidence of such 'hidden' age-related changes in these patients may be underestimated. The approximately 450 thalidomide survivors in the UK are now aged between 59 and 64, a time of onset of symptomatic degenerative musculoskeletal pathology, even for a population of this age without congenital differences. The emergence of hidden defects, combined with the cumulative effects of altered joint biomechanics with increasing age may predispose survivors to such pathology. Ghassemi Jahani et al. (2014) and Newbronner et al. (2019) found that the prevalence of arthritis is increased in thalidomide survivors as compared with the general population, affecting around 93% of patients at a mean age of 46 years. Even in their fourth decade, these survivors already showed worse patient-reported outcome measures (PROMs) as compared with baseline population values (Ghassemi Jahani et al., 2014). To our knowledge, there are no specific longitudinal studies with paired data, but comparison of PROMs between patients with a mean age of 46 in one study (Ghassemi Jahani et al., 2014) and a mean age of over 60 in another study (Markiewicz et al., 2023) revealed significantly worse function in older survivors.

The health-related quality of life (HRQoL) of survivors is also significantly worse than baseline population values. Despite increasing awareness and publication of the functional and HRQoL problems faced by survivors, up to 43% of survivors report difficulty accessing healthcare services (Nippert et al., 2002), with survey data showing that survivors



**Figure 4.** Radiological changes of the right shoulder joint showing severe glenoid dysplasia, with concave remodeling of the humeral head. This is due to constant excessive external rotation at the shoulder and has been described as a 'natural reverse shoulder replacement'.

perceive a lack of understanding of complex care needs as a significant barrier.

The hand surgery community must be mindful of the physical and social challenges faced by this group of patients to ensure ongoing appropriate care in the context of deteriorating disability. Managing the upper limb problems in this unique adult patient population will require easier and more direct access to appropriate surgical expertise. It is also important that hand surgery colleagues share their experience: although the number of referrals of these adult patients is likely to be small, it will probably increase as they age and access to care becomes more widely available.

### Management of the adult patient

As with any complex upper limb disorder, a holistic approach is emphasized in the management of the adult patient with thalidomide embryopathy. Working with multidisciplinary specialists with experience of these adult patients, including neurologists, dermatologists and therapists, is important. National organizations with extensive networks, such as The Thalidomide Trust in the UK, can provide additional support for patients and clinicians.

The most common presentations are pain, increasing restriction with activities of daily living and nerve-related symptoms, particularly carpal tunnel syndrome (Ohnishi and Hinoshita, 2017). The assessment focuses on the history of the presenting symptoms while taking into account how this affects their broader function, as pain and decreasing joint movement owing to new onset adult symptoms compound existing impairments (Newbronner and Atkin, 2018). It is important to gain a detailed understanding

causing harm to developing embryos (Beedie et al., 2016; Lecca et al., 2023).

The field of engineered analogues is moving forward rapidly, in part owing to the increased use of thalidomide to treat an increasing range of clinical conditions, including complications of COVID-19 (Vargesson and Stephens, 2021). It is likely that the beneficial actions in the adult, such as stabilizing vessels and preventing new vessel growth to treat conditions like HHT (Lebrin et al., 2010; Peng et al., 2015) will continue to be damaging to exposed embryos but improved understanding of these actions will help determine how thalidomide caused damage to the embryo and provide therapeutic insight into the treatment of such damage after birth.

The clinical experience gained from the early management of these patients as infants should not be underestimated. Although a tragedy, the large number of children who presented with thalidomide-induced congenital differences allowed a great deal of learning, with several landmark articles published in the treatment of congenital hand differences. These articles remain relevant, and the techniques are still being used, in particular the operation of centralization for radial dysplasia (Lamb, 1977). Other knowledge gained from that era included the classification of phocomelia and also the use of prostheses (Lamb, 1971).

Management by clinicians and centres with experience of adult thalidomide patients is necessary to manage age-related symptoms. The use of PROMs questionnaires and other more recent assessment methods highlight not just their current plight but also what may await any adult patient with a congenital hand difference, whether induced by thalidomide or not and should alert medical professionals to their ongoing needs.

**Acknowledgements** This article came about following the Authors presenting their thalidomide work at the 2022 FESSH (Federation of European Societies for Surgery of the Hand) Congress, London on 7 June 2022 in a special symposium entitled 'Thalidomide embryopathy of the Upper Limb'.


**Author contributions** Neil Vargesson: Conceptualization and author of the pathogenesis section. Geoffrey Hooper: Early management of the paediatric patient with a focus on surgery and prostheses. Grey Giddins and Alastair Hunter: Management of the adult patient. Paul Stirling: Age-related changes and selection of cases. Wee Lam: Conceptualization and overall direction of the manuscript. All authors were involved in the writing of the manuscript.

**Declaration of conflicting interests** The authors declare no potential conflicts of interest with respect to the research, authorship, and/or publication of this article.

**Funding** The authors received no financial support for the research, authorship, and/or publication of this article.

**Ethical approval** No ethical approval was necessary.

**Informed consent** Photographs of children were from archives and consent was obtained for the adult patient. Radiographs were anonymized.

**ORCID iD** Neil Vargesson  <https://orcid.org/0000-0001-8027-114X>

### References

- Asatsuma-Okumura T, Ando H, Simone MD et al. P63 is a cereblon substrate involved in thalidomide teratogenicity. *Nat Chem Biol.* 2019, 15: 1077–84.
- Asatsuma-Okumura T, Ito T, Handa H. Molecular mechanisms of the teratogenic effects of thalidomide. *Pharmaceuticals (Basel).* 2020, 13: 95.
- Bauer KS, Dixon SC, Figg WD. Inhibition of angiogenesis by thalidomide requires metabolic activation, which is species-dependent. *Biochem Pharmacol.* 1998, 55: 1827–34.
- Beedie SL, Huang PA, Harris EM et al. Role of cereblon in angiogenesis and in mediating the antiangiogenic activity of immunomodulatory drugs. *FASEB J.* 2020, 34: 11395–404.
- Beedie SL, Rore HM, Barnett S et al. In vivo screening and discovery of novel candidate thalidomide analogs in the zebrafish embryo and chicken embryo model systems. *Oncotarget.* 2016, 7: 33237–45.
- Buck-Gramcko D. Pollicization of the index finger. *J Bone Jt Surg.* 1971, 53-A: 1605–17.
- Buck-Gramcko D. Radialization as a new treatment for radial club hand. *J Hand Surg Am.* 1985, 10: 964–8.
- Chan C, McGee P, Hooper G et al. Re-examining the nomenclature of congenital failure of formation in the upper limb: a historical perspective. *J Hand Surg Eur Vol.* 2023. DOI: 10.1177/17531934231160400.
- Chandrangsu S, Sappayatosok K. p53, p63, p73 expression and angiogenesis in keratocystic odontogenic tumors. *J Clin Exp Dent.* 2016, 8: e505–11.
- Cheng J, Jiang J, He B et al. A phase 2 study of thalidomide for the treatment of radiation-induced blood brain barrier injury. *Sci Transl Med.* 2023, 15: eabm6543.
- Chowdhury G, Murayama N, Okada Y et al. Human liver microsomal cytochrome P450 3A enzymes involved in thalidomide 5-hydroxylation and formation of a glutathione conjugate. *Chem Res Toxicol.* 2010, 23: 1018–24.
- Davey MG, Towers M, Vargesson N, Tickle C. The chick limb: embryology, genetics and teratology. *Int J Dev Biol.* 2018, 62: 85–95.
- Dong W, Akasaka I, Komiyama A et al. Augmentation of pectoral fin teratogenicity by thalidomide in human cytochrome P450 3A-expressing zebrafish. *Pharmaceuticals (Basel).* 2023, 16: 368.
- Donovan KA, An J, Nowak RP et al. Thalidomide promotes degradation of SALL4, a transcription factor implied in Duane Radial Ray Syndrome. *Elife.* 2018, 7: e38420.

- Ema M, Ise R, Kato H et al. Fetal malformations and early embryonic gene expression response in cynomolgus monkeys maternally exposed to thalidomide. *Reprod Toxicol*. 2010, 29: 49–56.
- Ezaki M. Challenging the dogma: a straight wrist should be the goal in radial dysplasia. *J Hand Surg Eur*. 2021, 46: 14–20.
- Franks ME, Macpherson GR, Figg WD. Thalidomide. *Lancet*. 2004, 363: 1802–11.
- Frantz CH, O'Rahilly R. Congenital skeletal limb deficiencies. *J Bone Jt Surg Am*. 1961, 43: 1202–24.
- Furihata H, Yamanaka S, Honda T et al. Structural bases of IMiD selectivity that emerges by 5-hydroxythlidomide. *Nat Commun*. 2020, 11: 4578.
- Ghassemi Jahani SA, Danielson B, Karlsson J, Danielsson AJ. Long-term follow-up of thalidomide embryopathy: malformations and development of osteoarthritis in the lower extremities and evaluation of upper extremity function. *J Child Orthop*. 2014, 8: 423–33.
- Ghassemi Jahani SA, Danielsson A, Karlsson J, Brisby H. Middle-aged individuals with thalidomide embryopathy have undergone few surgical limb procedures and demonstrate a high degree of physical independence. *PLoS One*. 2017, 12: e0186388.
- Goldfarb CA, Manske PR, Busa R, Mills J, Carter P, Ezaki M. Upper-extremity phocomelia reexamined: a longitudinal dysplasia. *J Bone Jt Surg*. 2005, 87: 2639–48.
- Grammatico S, Cesini L, Petrucci MT. Managing treatment-related peripheral neuropathy in patients with multiple myeloma. *Blood Lymphat Cancer*. 2016, 6: 37–47.
- Hansen JM, Gong SG, Philbert M et al. Misregulation of gene expression in the redox-sensitive NF-kappa b-dependent limb outgrowth pathway by thalidomide. *Dev Dyn*. 2002a, 225: 186–94.
- Hansen JM, Harris KK, Philbert MA, Harris C. Thalidomide modulates nuclear redox status and preferentially depletes glutathione in rabbit limb versus rat limb. *J Pharmacol Exp Ther*. 2002b, 300: 768–76.
- Heim C, Maiwald S, Steinebach C et al. On the correlation of cereblon binding, fluorination and antiangiogenic properties of immunomodulatory drugs. *Biochem Biophys Res Commun*. 2021, 534: 67–72.
- Ito T, Ando H, Suzuki T et al. Identification of a primary target of thalidomide teratogenicity. *Science*. 2010, 327: 1345–50.
- Kimmeyer M, Lehmann L-J, Gerhardt C, Schmalz J. Development and function of a natural reverse shoulder in a patient with thalidomide-induced dysmelia. *JSES Rev Reports, Tech*. 2021, 1: 60–4.
- Knobloch J, Jungck D, Koch A. Apoptosis induction by thalidomide: critical for limb teratogenicity but therapeutic potential in idiopathic pulmonary fibrosis. *Curr Mol Pharmacol*. 2011, 4: 26–61.
- Knobloch J, Shaugnessy JD, Ruther U. Thalidomide induces limb deformities by perturbing the Bmp/Dkk1/Wnt signalling pathway. *FASEB J*. 2007, 21: 1410–21.
- Kohlhase J, Chitayat D, Kotzot D et al. SALL4 mutations in Okhiro syndrome [Duane-radial ray syndrome], acro-renalocular syndrome and related disorders. *Hum Mutat*. 2005, 26: 176–83.
- Kohlhase J, Holmes LB. Mutations in sall4 in malformed father and daughter postulated previously due to reflect mutagenesis by thalidomide. *Birth Defects Res A Clin Mol Teratol*. 2004, 70: 550–1.
- Lamb DW. Radial club hand. A continuing study of sixty-eight patients with one hundred and seventeen club hands. *J Bone Jt Surg Am*. 1977, 59: 1–13.
- Lamb DW, MacNaughtan AKM, Fragiadakis EG. Phocomelia of the upper limb. *Hand*. 1971, 3: 200–3.
- Lamb DW, Scott H, Lam WL, Gillespie WJ, Hooper G. Operative correction of radial club hand. A long-term follow-up of centralization of the hand on the wrist. *J Hand Surg Br*. 1997, 22: 533–6.
- Lebrin F, Srun S, Raymond K et al. Thalidomide stimulates vessel maturation and reduces epistaxis in individuals with hereditary hemorrhagic telangiectasia. *Nature Med*. 2010, 16: 420–8.
- Lecca D, Hsueh S-C, Luo W et al. Novel, thalidomide like, non-cereblon binding drug tetrafluorobornylphthalimide mitigates inflammation and brain injury. *J Biomed Sci*. 2023, 30: 16.
- Lenz W. Thalidomide and congenital abnormalities. *Lancet*. 1962, 1: 271–2.
- McBride W. Thalidomide and congenital malformations. *Lancet*. 1961, 1: 358.
- Mahony C, McMenemy S, Rafipay AJ et al. CPS49-induced neurotoxicity does not cause limb patterning anomalies in developing chicken embryos. *J Anat*. 2018, 232: 568–74.
- Mansour S, Baple E, Hall CM. A clinical review and introduction of the diagnostic algorithm for thalidomide embryopathy (DATE). *J Hand Surg Eur*. 2019, 44: 96–108.
- Markiewicz M, Stirling P, Brennan S, Hooper G, Lam W. Age-related changes in patients with upper limb thalidomide embryopathy in the United Kingdom. *J Hand Surg Eur Vol*. 2023. DOI: 10.1177/17531934231164093.
- Matyskiela ME, Couto S, Zheng X et al. SALL4 mediates teratogenicity as a thalidomide-dependent cereblon substrate. *NatChem Biol*. 2018, 14: 981–7.
- Merkle TP, Beckmann N, Bruckner T, Zeifang F. Shoulder joint replacement can improve quality of life and outcome in patients with dysmelia: a case series. *BMC Musculoskelet Disord*. 2016, 17: 185.
- Mileshkin L, Prince HM. The troublesome toxicity of peripheral neuropathy with thalidomide. *Leuk Lymphoma*. 2006, 47: 2276–9.
- Mueller M, Lewis DJ. Implementation of a pregnancy prevention Programme (PPP) with a controlled distribution system (CDS) for the generic teratogenic phthalimides thalidomide, lenalidomide and pomalidomide. *Ther Innov Regul Sci*. 2021, 55: 1155–64.
- Newbronner E, Atkin K. The changing health of thalidomide survivors as they age: a scoping review. *Disabil Health J*. 2018, 11: 184–91.
- Newbronner E, Glendinning C, Atkin K, Wadman R. The health and quality of life of thalidomide survivors as they age – evidence from a UK survey. *PLoS One*. 2019, 14: e0210222.
- Newman RJ. Shoulder joint replacement for osteoarthritis in association with thalidomide-induced phocomelia. *Clin Rehabilitation*. 1999, 13: 250–2.
- Nichols PJR, Rogers EE, Clark MS, Stamp WG. The acceptance and rejection of prostheses by children with multiple congenital limb deformities. *Artif Limbs*. 1968, 12: 1–13.
- Nicotra A, Newman C, Johnson M. Peripheral nerve dysfunction in middle-aged subjects born with thalidomide embryopathy. *PLoS One*. 2016, 11: e0152902.
- Nippert I, Edler B, Schmidt-Herterich C. 40 years later: the health related quality of life of women affected by thalidomide. *Community Genet*. 2002, 5: 209–16.
- Ohnishi S, Hinoshita F (Eds.) Guide for the management of thalidomide embryopathy. Tokyo: Research Group on the Various Problems Regarding the Health and Living Situations of Thalidomide-Impaired People in Japan, 2017.
- Oshima Y, Okutsu I, Hamanaka I, Motomura T. Carpal tunnel syndrome accompanying radial dysplasia due to thalidomide embryopathy. *J Hand Surg Br*. 2006, 31: 342–4.

- Parman T, Wiley MJ, Wells PG. Free radical-mediated oxidative DNA damage in the mechanism of thalidomide teratogenicity. *Nat Med*. 1999, 5: 582–5.
- Peach ML, Beedie SL, Chau CH et al. Antiangiogenic activity and in silico cereblon binding analysis of novel thalidomide analogs. *Molecules*. 2020, 25: 5683.
- Peng H-L, Yi Y-F, Zhou S-K, Xie S-S, Zhang G-S. Thalidomide effects in patients with Hereditary Hemorrhagic Telangiectasia during therapeutic treatment and in Fli-EGFP transgenic zebrafish model. *Chin Med J (Engl)*. 2015, 128: 3050–4.
- Rose MI, Rosson GD, Elkwood AI, Dellon AL. Thalidomide-induced neuropathy: treatment by decompression of peripheral nerves. *Plast Reconstr Surg*. 2006, 117: 2329–32.
- Ruffing L. Evaluation of thalidomide children. *Birth Defects Orig Artic Ser*. 1977, 13: 287–300.
- Sewell MD, Al-Hadithy N, Higgs D, Bayley I, Falworth M, Lambert S. Complex shoulder arthroplasty in patients with skeletal dysplasia can decrease pain and improve function. *J Shoulder Elbow Surg*. 2014, 23: 1499–507.
- Siamwala JH, Veeriah V, Priya MK et al. Nitric oxide rescues thalidomide mediated teratogenicity. *Sci Rep*. 2012, 2: 679.
- Sulamaa M, Ryöppy S. Early treatment of congenital bone deficits of the extremities. Aftermath of thalidomide disaster. *Lancet*. 1964, 1: 130–2.
- Tajima T, Wada T, Yoshizawa A et al. Internal anomalies in thalidomide embryopathy: results of imaging screening by CT and MRI. *Clin Radiol*. 2016, 71: 1199 e1–7.
- Tamilarasan KP, Kolluru GK, Rajaram M, Indhumathy M, Saranya R, Chatterjee S. Thalidomide attenuates nitric oxide mediated angiogenesis by blocking migration of endothelial cells. *BMC Cell Biol*. 2006, 7: 17.
- Tang C-T, Zhang Q-W, Wu S et al. Thalidomide targets EGFL6 to inhibit EGFL6/PAX6 axis-driven angiogenesis in small bowel vascular malformation. *Cell Mol Life Sci*. 2020, 77: 5207–21.
- Therapontos C, Erskine L, Gardner ER, Figg WD, Vargesson N. Thalidomide induces limb defects by preventing angiogenic outgrowth during early limb formation. *Proc Natl Acad Sci USA*. 2009, 26: 8673–8.
- Tytherleigh-Strong G, Hooper G. The classification of phocomelia. *J Hand Surg Br & Eur*. 2003, 28: 215–7.
- Umaphathi T, Chaudhry V. Toxic neuropathy. *Curr Opin Neurol*. 2005, 18: 574–80.
- Vargesson N. Thalidomide embryopathy: an enigmatic challenge. *ISRN Developmental Biology*. 2013, 2013: 241016.
- Vargesson N. Thalidomide-induced teratogenesis: history and mechanisms. *Birth Defects Res Part C*. 2015, 105: 140–56.
- Vargesson N. The teratogenic effects of thalidomide on limbs. *J Hand Surg Eur*. 2019, 44: 88–95.
- Vargesson N, Hootnick DR. Arterial dysgenesis and limb defects: clinical and experimental examples. *Reprod Toxicol*. 2017, 70: 21–9.
- Vargesson N, Stephens T. Thalidomide: history, withdrawal, renaissance and safety concerns. *Expert Opinion on Drug Safety*. 2021, 20: 1455–7.
- Vianna FS, Lopez-Camelo JS, Leite JC et al. Epidemiological surveillance of birth defects compatible with thalidomide embryopathy in Brazil. *PLoS One*. 2011, 6: e21735.
- Yabu T, Tomimoto H, Taguchi Y, Yamaoka S, Igarashi Y, Okazaki T. Thalidomide-induced antiangiogenic action is mediated by ceramide through depletion of VEGF receptors, and is antagonized by sphingosine-1-phosphate. *Blood*. 2005, 106: 125–34.
- Yamanaka S, Hidetaka Murai H et al. Thalidomide and its metabolite 5-hydroxythalidomide induce teratogenicity via the cereblon neosubstrate PLZF. *EMBO J*. 2021, 40: e105375.
- Yamazaki H, Suemizu H, Shimizu M et al. In vivo formation of dehydroxylated and hltathione conjugate metabolites derived from thalidomide in and 5-hydroxythalidomide in humanized TK-NOG mice. *Chem Res Toxicol*. 2012, 25: 274–6.
- Zara G, Ermani M, Rondione R, Arienti S, Doria A. Thalidomide and sensory neurotoxicity: a neurophysiological study. *J Neurol Neurosurg Psychiatry*. 2008, 79: 1258–61.

**Acknowledgement: This article is re-published with permission from the Editor which was appeared in the Journal of Hand Surgery (European Volume) 2023, Vol. 48(8) 699–709.**

